

Child Abuse – Nonaccidental Injury (NAI)

Issues and Controversies for Neuroradiology in the Era of Evidence-Based Medicine

Patrick D. Barnes, MD
Chief, Pediatric Neuroradiology
Director, Pediatric MRI & CT Center
Professor of Radiology
Lucile Packard Children's Hospital
Stanford University Medical Center
Phone 650-823-9585
Fax 650-497-8745
pbarnes@stanford.edu
<http://www.stanford.edu/~pbarnes/>
December 2009

Abstract

Because of the widely acknowledged controversy involving the determination of nonaccidental injury (NAI), or child abuse, the radiologist must be familiar with the issues, the literature, and the principles of evidence-based medicine in order to understand the proper role of imaging. Children with suspected NAI must not only receive protective evaluation, but also require a timely and complete clinical and imaging workup, to include primary consideration for the mimics of abuse. The imaging findings cannot stand alone and must be correlated with clinical findings (including current and past history), adequate laboratory testing, and proper pathologic and forensic examinations. In the context of evidence-based medicine, along with recent legal and judicial reviews, challenges to the *traditional* tenets of NAI indicate that

medical and imaging evidence cannot reliably diagnose "intentional" injury. Only the child protection investigation may provide the basis for "inflicted" injury in the context of *supportive* clinical, imaging, biomechanical, or pathology findings.

Introduction

Nonaccidental, inflicted, or intentional, trauma is said to be the most frequent cause of traumatic injury in infants with peak incidence at about 6 months of age, and accounting for about 80% of the deaths from traumatic brain injury in children under the age of two years [1-9]. Nonaccidental injury (NAI), or nonaccidental trauma (NAT), is the more recent terminology applied to the *traditional* labels "child abuse", "battered child syndrome", and "shaken baby syndrome" (SBS). A more recent restatement of the *traditional* definition of SBS is that it represents a form of physical NAI to infants characterized by *the triad* of (1) subdural hemorrhage - SDH, (2) retinal hemorrhage - RH, and (3) encephalopathy (i.e. diffuse axonal injury - DAI) occurring in the context of inappropriate or inconsistent history (particularly when *unwitnessed*), and commonly accompanied by other apparently inflicted injuries (e.g. skeletal) [1]. This empirical formula is under challenge by evidence-based medical and legal principals [10-23].

Traumatic Central Nervous System Injury

The spectrum of traumatic central nervous system (CNS) injury has been categorized in a number of ways [7,23]. Clinically and pathologically, *primary injury* (e.g. contusion, shear injury) directly results from the initial traumatic force and is immediate and irreversible. *Secondary injury* arises from, or is associated with, the primary injury and is potentially reversible (e.g. swelling, hypoxia-ischemia, seizures, herniation). *Traditional* biomechanics teaches that *impact loading* is associated with *linear* forces and produces localized cranial deformation and “focal” injury (e.g. fracture, contusion, epidural hematoma - EDH). Accidental injury (AI) is said to be typically associated with impact and, with the exception of EDH, is usually not life threatening. *Impulsive loading* refers to *angular acceleration / deceleration forces* resulting from sudden non-impact motion of the head on the neck (i.e. whiplash) and produces “diffuse” injury, i.e. shear strain deformation and disruption at tissue interfaces (i.e. SBS including bridging vein rupture with SDH and white matter shear injury – DAI). The young infant is said to be particularly vulnerable to the latter mechanism (i.e. SBS) because of weak neck muscles, a relatively large head, and an immature brain. SBS is *traditionally* postulated to result in *the triad* of primary traumatic injury (i.e. SDH, RH, and DAI) which has been reportedly associated with the most severe and fatal CNS injuries.

Stated assault mechanisms in NAI have included battering, shaking, impact, shaking-impact, strangulation, suffocation, and combined assaults (shake-bang-choke) [1-9,23]. The spectrum of

CNS injury occurring with NAI overlaps that due to AI. However, certain patterns have been *traditionally* reported to be characteristic of, or highly suspicious for, NAI [7,9,23]. These include multiple or complex cranial fractures [Fig.1], acute interhemispheric SDH [Fig.2], acute-hyperacute SDH [Fig.3], DAI, chronic SDH, and the combination of chronic and acute SDH [Fig.4]. The latter is said to be indicative of more than one abusive event. Imaging evidence of CNS injury may occur with, or without, other clinical findings of trauma (e.g. bruising) or with other *traditionally* “higher specificity” imaging findings of abuse (e.g. classic metaphyseal lesions [CML] or rib fractures) [7-9] [Fig.5]. Therefore, clinical and imaging findings of injury *out of proportion to the history of trauma*, and injuries of *different ages*, are two *traditional* criteria used by medical professionals, including radiologists, to make a medical diagnosis and offer expert testimony that such “forensic” findings are “proof” of NAI / SBS, particularly when encountered in the *premobile*, young infant.

Evidence-based Medicine & the Law

Evidence-based medicine (EBM) is now the guiding principle in establishing standards and guidelines as medicine has moved from an *authoritarian* to an *authoritative* era in order to overcome *bias* and *ideology* in medicine [23-27b]. EBM quality of evidence (QOE) ratings of the literature (e.g. classes I-IV) are based upon levels of accepted scientific methodology and biostatistical

significance (e.g. p-values) and applies to every aspect of medicine including diagnostics, therapeutics, and forensics. EBM analysis reveals that few published reports in the *traditional* NAI / SBS literature merit a QOE rating above class IV (e.g. expert opinion alone) [10]. Such low ratings do not meet EBM recommendations for standards (e.g. level A) or for guidelines (e.g. level B). Difficulties exist in the rational formulation of a “medical” diagnosis or “forensic” determination of NAI / SBS based on an alleged event (e.g. shaking) that is inferred from clinical, imaging, or pathologic findings in the *subjective* context of (a) an “unwitnessed” event, (b) a “noncredible” history, or (c) an admission or confession under dubious circumstances [11]. This problem is further confounded by the lack of consistent and reliable criteria for the diagnosis of NAI / SBS, and that much of the *traditional* literature on child abuse consists of anecdotal case series, case reports, reviews, opinions, and position papers [10,11,28,29]. Many reports include cases having impact injury which undermines the SBS hypothesis by imposing a “shaking-impact” syndrome. Also, the inclusion criteria provided in many reports are criticized as arbitrary. Examples include “suspected abuse”, “presumed abuse”, “likely abuse”, and “indeterminate” [28,29]. Furthermore, the diagnostic criteria often appear to follow “circular logic” such that the inclusion criteria (e.g. the *triad* equals *SBS/NAI*) becomes the conclusion (i.e. *SBS/NAI* equals the *triad*).

Regarding the *rules of evidence* within the justice system, there are established *standards* for the admissibility of expert testimony

[12,13,13a,17a,30]. The *Frye* standard requires only that the testimony be *generally accepted in the relevant scientific community*. The Daubert (and Kumho) standard requires assessment of the *scientific reliability* of the testimony. A criticism of the justice system is that the application of these standards *vary* with the jurisdiction (e.g. according to state v. federal law). Additional legal standards regarding *proof* are also applied in order for the *triar of fact* (e.g. judge or jury) to make the determination of civil liability or criminal guilt. In a civil action (e.g. medical malpractice lawsuit), money is primarily at risk for the defendant health care provider, and proof of liability is based upon *a preponderance of the evidence* (i.e. at least 51% scientific or medical certainty).

In a criminal action, life or liberty is at stake for the defendant, including the permanent loss of child custody [12,13,13a,17a,30]. In such cases, the defendant has the constitutional protection of *due process* that requires a higher level of proof. This includes the principle of *innocent until proven guilty beyond a reasonable doubt* with the *burden of proof* on the prosecution and based upon *clear and convincing evidence*. However, no percentage of level of certainty is provided for these *standards of proof* in most jurisdictions. Furthermore, only a preponderance of the *medical* evidence (i.e. minimum of 51 % certainty) is required to support proof of guilt whether the medical expert testimony complies with the *Frye* standard (i.e. general acceptance requirement) or the Daubert standard (i.e. scientific reliability requirement). A further

criticism of the criminal justice process is that in NAI cases, medical experts have defined SBS / NAI as “the presence of injury (e.g. the triad) without a sufficient historical explanation”, and that this definition unduly shifts the burden to the defendant to establish innocence by proving the expert theory wrong.

The “Medical” Prosecution of NAI and its EBM Challenges

Traditionally, the prosecution of NAI has been based upon the presence of any one, or more, of the injury components of *the triad* as supported by the premises that (a) shaking alone in an otherwise healthy child can cause SDH leading to death, (b) that such injury can never occur on an accidental basis (e.g. short fall) because it requires a massive force equivalent to a motor vehicle accident or a fall from a multi-story building, (c) that such injury is immediately symptomatic and cannot be followed by a lucid interval, and (d) that changing symptoms in a child with prior head injury indicates newly inflicted injury and not a spontaneous rebleed [12,13,13a,17a,23]. Using this reasoning, the last caretaker is automatically guilty of abusive injury, especially if not witnessed by an independent observer. Also, it has been asserted that RHs of a particular pattern are diagnostic of SBS / NAI.

Reports from clinical, biomechanical, pathology, forensic, and legal disciplines, within and outside of the child maltreatment literature, have challenged the evidence base for NAI / SBS as the only cause for one or more elements of *the triad* [10-23]. Such

reports indicate that *the triad* may also be seen with accidental injury (including *witnessed* short falls, lucid intervals, and rehemorrhage) [Figs 6,7], as well as in medical conditions. These are the “mimics” of NAI and often present as acute life threatening events (ALTE) [31-34]. The medical mimics include hypoxia-ischemia (e.g. apnea, choking, respiratory or cardiac arrest) [Fig.2,6,7], ischemic injury (e.g. arterial vs. venous occlusive disease) [Fig.8], vascular anomalies (e.g. arteriovenous malformation –AVM) [Fig.9], seizures [Fig.2], infectious or post-infectious conditions [Fig.10], coagulopathies [Fig.11], fluid-electrolyte derangement, and metabolic or connective tissue disorders including vitamin deficiencies and depletions (e.g. C,D,K) [Figs.1,5,13] [9,23].

Many ALTE appear to be *multifactorial* and involve a combination, sequence, or cascade of *predisposing* and *complicating* events or conditions [23,31]. As an example, an infant may suffer a head impact, or choking spell, followed by seizures or apnea, and then undergoes a series of interventions including prolonged or difficult resuscitation and problematic airway management with subsequent hypoxia-ischemia and coagulopathy [Figs 2,6,7,11]. Another example is a young infant with a predisposing condition such as infectious illness, fluid-electrolyte imbalance, metabolic disorder, or a coagulopathy, who then suffers seizures, respiratory arrest, and resuscitation with hypoxia-ischemia [Figs 2,8,10-13]. In many cases of alleged SBS/NAI it is often assumed that nonspecific *premorbid* symptoms

(e.g. irritability, lethargy, poor feeding) in an “otherwise healthy” infant is an indicator of ongoing abuse or that such symptoms become the inciting factor for the abuse. A thorough and complete medical investigation in such cases may reveal that the child is “not” otherwise healthy and, in fact, is suffering from a medical condition that progresses to an ALTE [10-23].

Biomechanical Challenges

The “mechanical” basis for SBS as originally hypothesized by Guthkelch (1971) and Caffey (1972, 1974), and then subsequent authors, was extrapolated from a single scientific source [5,6,35]. The biomechanical and neuropathological experiment conducted by Ommaya (1968) used a whiplash model comprised of *adult* rhesus monkeys mounted on a piston-driven sled to determine the angular acceleration threshold (i.e. 40g) for head injury (i.e. concussion, SDH, shear injury) as well as neck injury [36]. From this experiment, it was assumed by Gutkelch and Caffey that manual shaking of an infant could generate these same forces and produce the triad [37-39]. Caffey stated “current evidence, though manifestly incomplete and largely circumstantial, warrants a nationwide educational campaign on the potential pathogenicity of habitual shaking of infants [6,35].” As a result, centers for child abuse (e.g. Kempe, Chadwick) were established all across the country, along with mandated reporting laws, with the anticipation of further research into these issues.

Probably the first and most widely reported biomechanical test of the SBS hypothesis was conducted by Duhaime et al (1987) who measured the angular accelerations associated with adult manual shaking (11g) and impact (52g) in a 1-month old infant anthropomorphic test device (ATD) [40]. Only accelerations associated with impact (4-5 times that associated with shakes), on an unpadded or padded surface, exceeded the injury thresholds determined by Ommaya. Furthermore, in the same study, the authors reported a series of 13 fatal cases of NAI / SBS in which all had evidence of blunt head impact (more than half noted only at autopsy) [40]. The authors concluded that CNS injury in SBS / NAI in its most severe form is usually not caused by shaking alone. Their results contradicted many of the original reports that had relied upon the “whiplash” mechanism as causative of “the triad.” These authors also concluded that fatal cases of SBS / NAI, unless in children with *predisposing factors* (e.g. subdural hygroma, atrophy, etc.), are not likely to result from shaking during play, feeding, swinging, or from more vigorous shaking by a caretaker for discipline. They suggested the use of the new term “shaken-impact syndrome [40].”

More recently, Prange et al (2003) using a 1.5 month-old ATD showed that (a) peak angular accelerations and maximum change in angular velocity increased with increasing fall height and surface hardness, (b) that inflicted impacts against hard surfaces were more likely to be associated with brain injury than falls from less than 1.5m or from vigorous shaking, and (c) there are no data

to show that such measured parameters during shaking or inflicted impacts against unencased foam is sufficient to cause SDH or TAI in an infant [41]. Their results along with other animal, cadaver, and clinical case studies also indicate that SDH and death from minor falls in infants are more likely to occur with falls > 1.5 m (4-5 ft.) and on to a hard surface [41]. With further improvements in ATDs, more recent experiments indicate that maximum head accelerations may exceed injury reference values (IRV) at lower fall heights than previously determined [Table 1; 41a]. Subsequent studies with varying QOE ratings and using biomechanical (ATD), animal, or computer models have either supported, or failed to invalidate, the Duhaime study [42-50]. Some critics of the Duhaime and Prange studies (Cory & Jones 2003, Roth et al 2006, Pierce & Bertocci 2008) also contend that there is no adequate human infant surrogate yet designed to properly test “shaking vs. impact [44,49,50].” Even more recently, Coats and Margulies (2008) used an innovative 3D biomechanical technique to provide preliminary verification of prior cadaver drop results that infant linear skull fractures may occur with head-first fall heights 0.9 m (3 feet) onto carpet and 0.6-0.9 m (2-3 feet) onto concrete [44a].

Other reports (Ommaya et al 2002, Bandak 2005, etc.) also show that shaking alone cannot result in brain injury (i.e. *the triad*) unless there is concomitant structural failure with injury to the neck, cervical spinal column, or cervical spinal cord, since these are the “weak links” between the body and head of the infant

[42,45]. Although Bandak's results were criticized by Margulis et al [45a], to whom Bandak subsequently responded [45b], Margulis et al acknowledged the possibility for neck injury during severe shaking without impact. Spinal cord injury without radiographic abnormality (SCIWORA), whether AI or NAI, is an important form of primary neck and spinal cord injury with secondary brain injury [Fig.7] [51]. For example, a falling infant experiences a head-first impact with subsequent neck hyperextension, or hyperflexion, from the force of the trailing body mass. There is resultant upper spinal cord injury without detectable spinal column injury on plain films or CT. Compromise of the respiratory center at the cervico- medullary junction results in hypoxic brain injury including the "thin" SDH [Fig.7]. CT often shows the brain injury, but only MRI may show the additional neck or spinal cord injury.

The minimal force required to produce one or more of the elements of the triad has yet to be established. However, from the current evidence base in biomechanical science, one may reasonably conclude that (1) shaking may not produce *direct* brain injury, but may cause *indirect* brain injury if associated with neck and cervical spinal cord injury, (2) angular acceleration / deceleration injury forces clearly occur with impact trauma, (3) that such injury on an accidental basis does not require a force that can only be associated with motor vehicle accident or a multi-story fall, (4) that household (i.e. short-distance falls) may produce direct or indirect brain injury, (5) that in addition to fall height, impact surface and type of landing are important factors, and (6) that head-first impacts in

young infants not having developed a defensive reflex (e.g. extension of a limb to break the fall) are the most dangerous and may result in direct or indirect brain injury (e.g. SCIWORA).

Neuropathological Challenges

Probably the first and largest systematic neuropathological study in alleged SBS / NAI (53 cases) was reported by Geddes et al (2001) [52,53]. The findings in their 37 infant cases (age < 9 months) indicate (a) only 8 infants had no evidence of impact with only one case of admitted shaking, (b) that the cerebral swelling in young infants is more often due to “diffuse” axonal injury of hypoxic-ischemic encephalopathy (HIE) rather than traumatic axonal, or shear, injury (TAI); (c) that although fracture, “thin” SDH (e.g. dural vascular plexus origin), and RH are commonly present, the usual cause of death was increased intracranial pressure from brain swelling associated with HIE [Fig.2]; and, (d) that cervical epidural hemorrhage and focal axonal brain stem, cervical cord, and spinal nerve root injuries were characteristically seen in these infants (most with impact). Such upper cervical cord / brainstem injury may result in apnea / respiratory arrest and be responsible for the HIE. In the older infant and child case group (16 victims: ages 13 months to 8 years), the pathologic findings were primarily those of the “battered child or adult trauma syndrome” including extracranial injuries (e.g. abdominal), large SDH (i.e. bridging vein rupture), and TAI.

Additional neuropathologic series by Geddes et al (2003, 2004) have shown that SDH are also seen in non-traumatic fetal, neonatal, and infant brain injury cases and that such SDH are actually of intradural vascular plexus origin rather than bridging cortical vein origin [54,55]. The common denominator in these cases is likely a combination of cerebral venous hypertension and congestion, arterial hypertension, brain swelling, immaturity with vascular fragility further compromised by HIE or infection [Fig. 2], This “unified hypothesis” of Geddes et al has received criticism in nonscientific reviews and surveys (Punt et al 2004, Minns 2005, Byard et al 2007, David 2008, Jaspán 2008) [21,22,56-58]. However, Geddes et al findings and conclusions have been validated by the research of Cohen et al (2008), as well as others [59-62b]. In their post-mortem series, Cohen et al described 25 fetuses (gestational age range 26-41 weeks) and 30 neonates (postnatal age range 1 hour – 19 days) with HIE who also had *macroscopic* intradural hemorrhage (IDH), including frank parietal SDH in two-thirds. The IDH component was most prominent along the posterior falx and tentorial vascular plexuses (i.e. interhemispheric fissure) [Fig.2]. They concluded from their work, along with the findings of other cited researchers, that IDH and SDH are commonly associated with HIE (including the targeting of claudin-5, a key neurovascular tight-junction molecule), and particularly when associated with increases in central venous pressure [63]. This also explains the frequency of RH associated with perinatal events [64].

From the evidence base in forensic pathology, one may conclude that (1) shaking may not cause direct brain injury, but may cause indirect brain injury (i.e. HIE) if associated with cervical spinal cord injury, (2) that impact may produce direct or indirect brain injury (e.g. SCIWORA), (3) that the pattern of brain edema with thin SDH (dural vascular plexus origin) may reflect HIE whether due to AI or NAI, and (4) that the same pattern of injury may result from non-traumatic or medical causes (e.g. HIE from any cause of ALTE). Furthermore, since the observed edema does not represent TAI (which results in immediate neurologic dysfunction), a lucid interval is possible particularly in the infant whose sutured skull and dural vascular plexus have the distensibility to tolerate early increases in intracranial pressure. Also, the lucid interval invalidates the premise that the last caretaker is always responsible in alleged NAI.

Clinical Challenges.

Doubt has been raised in the literature that NAI / SBS is the cause in all *traumatic* cases manifesting the *triad*. In the prosecution of NAI, as previously mentioned, it is often stipulated that short falls cannot be associated with serious (e.g. fatal) head injury or a lucid interval. *Traditionally*, it has also been stipulated that non-intentional new bleeding in an existing SDH is always minor, that SDH does not occur in benign extracerebral collections, and that symptomatic or fatal new bleeding in SDH requires newly inflicted trauma [12,13,23]. A number of past and current reports refute the

significance of low level falls in children, including in-hospital and outpatient clinic series [65-72]. However, there are other reports, including emergency medicine, trauma center, neurosurgical, and medical examiner series, that indicate a heightened need for concern regarding the potential for serious intracranial injury associated with “minor” or “trivial” trauma scenarios, particularly in infants [72-93]. This includes reports of skull fracture or acute SDH from accidental simple falls in infants, SDH in infants with predisposing wide extracerebral spaces (e.g. benign extracerebral collections of infancy, chronic subdural hygromas, arachnoid cyst, etc.) [Figs 4,14,15] , and fatal pediatric head injuries due to *witnessed*, accidental short-distance falls, including those with a lucid interval, SDH, RH, and malignant cerebral edema [Fig. 6]. Also included are infants with chronic SDH from prior trauma (e.g. at birth) who then develop rehemorrhage [Figs 1,4,14].

Short falls, lucid intervals, and malignant edema. Hall et al (1989) reported that 41% of childhood deaths (mean age 2.4 yr.) from head injuries associated with AI were from low level falls (3 feet or less), while running, or down stairs [65]. Chadwick et al (1991) reported fatal falls of less than 4 feet in 7 infants, but considered the histories unreliable [66]. Plunkett (2001) reported witnessed fatal falls of 2-10 feet in 18 infants and children, including those with SDH, RH, and lucid intervals [76]. Greenes and Schutzman (1998) reported intracranial injuries, including SDH, in 18 asymptomatic infants with falls of 2 feet to 9 stairs [77]. Christian

et al (1999) reported 3 infants with unilateral RH and SDH / SAH due to witnessed accidental household trauma [83].

Denton and Mileusic (2003) reported a witnessed, accidental 30-inch fall in a 9 month old infant with a 3 day lucid interval before death [79]. Murray et al (2000) reported more intracranial injuries in young children (49% < age 4 yr.; 21% < age 1 yr.) with reported low level falls (< 15 feet), both AI and NAI [80]. Kim et al (2000) reported a high incidence of intracranial injury in children (ages 3 mo. – 15 yr.; 52% < age 2yr.) accidentally falling from low heights (3-15 feet; 80% < 6 feet; including 4 deaths) [81]. Because of the “lucid” intervals in some patients, including initially favorable Glasgow Coma scores (GCS) with subsequent deterioration, both Murray and Kim expressed concern regarding caretaker delays and medical transfer delays contributing to the morbidity and mortality in these patients [74-76,78-81].

Bruce et al (1981) reported one of the largest pediatric series of head trauma (63 patients, ages 6 months to 18 years), both AI and NAI, associated with “malignant brain edema” and SAH / SDH [Fig.6] [75]. In the higher GCS (>8) subgroup, there were 8 with a lucid interval and all 14 had complete recovery. In the lower GCS (<= 8) subgroup, there were 34 with immediate and continuous coma, 15 with a lucid interval, 6 deaths, and 11 with moderate to severe disability. More recently, Steinbok et al (2006) reported 5 children (4 < age 2yr.; 3 falls) with witnessed AI, including SDH and cerebral edema detected by CT 1-5 hours post-event [82]. All

experienced immediate coma with rapid progression to death [Fig.6].

Benign extracerebral collections (BECC). BECC of infancy (aka benign external hydrocephalus - BEH, benign extracerebral subarachnoid spaces – BESS) is a common and well-known condition characterized by diffuse enlargement of the subarachnoid spaces [85-94]. A transient disorder of cerebrospinal fluid circulation, probably due to delayed development of the arachnoid granulations, is widely accepted as the cause and develops from birth. BECC is typically associated with macrocephaly, but may also occur in infants with normal or small head circumferences, including premature infants. As with any cause of craniocerebral disproportion (e.g. BECC, hydrocephalus, chronic SDH or hygroma, arachnoid cyst, underdevelopment or atrophy), there is a susceptibility to SDH that may be spontaneous or associated with “trivial” trauma [Figs 4,14]. A recent large series report and review by Hellbusch (2007) emphasizes the importance of this predisposition and cites other confirmatory series and case reports (30 references) [93]. Papasian and Frim (2003) designed a theoretical model that predicts the predisposition of BEH to SDH with minor head trauma [88]. Piatt’s case report (1999) of BECC with SDH (27 references), including RH, along with McNeely et al case series (2006) are further warnings that this combination is far from specific for SBS / NAI [86,92].

Birth Issues. In addition to the examples cited above (e.g. short falls, BECC), another important but often overlooked factor is birth-related trauma [7,23,95-109]. This includes “normal” as well as complicated labor and delivery events (e.g. pitocin augmentation, prolonged labor, vaginal delivery, instrumented delivery, c-section, etc.). It is well-known that acute SDH often occurs even with the normal birth process, and that this predisposes to chronic SDH, including in the presence of BECC [Figs 1,4,14]. Intracranial hemorrhages, including SDH and RH, have been reported in a number of CT and MRI series of “normal” neonates including a frequency of 50% by Holden et al (1999), 8% by Whitby et al (2004), 26% by Looney et al (2007), and 46% by Rooks et al (2008) [95,97-99]. Chamnanvanakij et al (2002) reported 26 symptomatic term neonates with SDH over a 3-year period following uncomplicated deliveries [96]. Long-term followup imaging has not been provided in many of these series, although Rooks et al did report one child in their series who developed SDH with rehemorrhage superimposed upon BECC [Fig.16] [99].

Chronic SDH and re-hemorrhage. Chronic SDH is one of the most controversial topics in the NAI vs. AI debate [1-9,19,21-23,37-39]. The “unexplained” SDH is often ascribed to NAI. By definition, a newly discovered chronic SDH started as an acute SDH that, for whatever reason, may have been “subclinical.” There is likely more than one mechanism for SDH which has prompted a revisiting of the concept of the “subdural compartment” [19,55,62-

62b,110,111]. Mack et al have provided an updated review on the this important topic **[110]**. In some cases of infant trauma, dissection at the relatively weak dura-arachnoid borderzone (i.e. dural border cell layer - DBCL) may allow cerebrospinal fluid (CSF) to collect and enlarge over time as a dural interstitial (i.e. intradural) hygroma. In other cases, there is bridging vein rupture within the dural interstitium that results in an acute subdural or intradural hematoma that extends along the DBCL. Further yet, traumatic disruption of the dural vascular plexus (i.e. venous, capillary, lymphatic), which is particularly prominent in the young infant, may also produce an acute intradural hematoma. Some of these collections undergo resorption while others progress to become chronic SDH. Some progressive collections may represent mixed CSF-blood collections **[Figs 1,4,14,16]**.

The pathology and pathophysiology of neomembrane formation in chronic SDH, including rebleeding, is well-established in adults and appears similar, if not identical, to that in infants **[112-133]** . While acute SDH is most often due to impact or deformational trauma, whether AI or NAI, it must be differentiated from chronic SDH with re-hemorrhage. Progression of chronic SDH and rehemorrhage is likely related to capillary leakage and intrinsic thrombolysis **[112,113]**. Other factors include dural vascular plexus hemorrhage associated with increases in intracranial or central venous pressures (e.g. birth trauma, congenital heart disease, venous thrombosis, dysphagic choking), or with increased meningeal arterial pressure (e.g. reperfusion following hypoxia-

ischemia) with resultant acute hemorrhage (or re-hemorrhage) in “normal” infants or superimposed upon “predisposing” chronic BECC, hygromas, hematomas, or arachnoid cysts [Figs 1,2,4,14-16] [19,31,55,62,85-94,110,111]. The phenomenon of acute infantile SDH, whether AI or NAI, evolving to chronic SDH and re-hemorrhage, including RH, is well-documented in several neurosurgical series reports including Aoki et al (1984, 1990), Ikeda et al (1987), Parent (1992), Howard et al (1993), Hwang et al (2000), Vinchon (2002,2004), and others [114,117-119,122-124].

From the clinical evidence base, in addition to the biomechanical science and forensic pathology data bases, one may conclude that (1) significant head injury, including SDH and RH, may result from low fall levels, (2) such injury may be associated with a lucid interval, (3) in some, the injury may result in immediate deterioration with progression to death, (4) BECC predisposes to SDH, (5) SDH may date back to birth, and (6) rehemorrhage into an existing SDH occurs in childhood and may be serious.

RH Challenges.

Many guidelines for diagnosing NAI depend upon the presence of RH, including those of a particular pattern (e.g. retinal schisis, perimacular folds), and based upon the theory of vitreous traction due to inflicted acceleration / deceleration forces (e.g. SBS) [134-153]. However, the specificity of RH for NAI has been repeatedly challenged. Plunkett (2001) reported RH in 2/3 of eye exams in

children with fatal AI [76]. Goldsmith and Plunkett (2004) reported a child with extensive bilateral RH in a videotaped fatal accidental short fall [74]. Lantz et al (2004) reported RH with perimacular folds in an infant crush injury [144]. Gilles et al (2003) reported the appearance and progression of RH with increasing intracranial pressure following head injury in children [142]. Obi et al (2007) reported RH with schisis and folds in two children, one with AI and the other with NAI [147]. Forbes et al (2007) reported RH with epidural hematoma in five infant AI cases [148]. From a research perspective, Brown et al (2007) found no eye pathology in their fatal shaken animal observations [150]. Binenbaum et al (2007) observed no eye abnormalities in piglets subjected to acceleration/deceleration levels >20 times what Prange et al (2003) predicted possible in inflicted injury [41,149]. Emerson et al (2007) found no support for the vitreous traction hypothesis as unique to NAI [151].

The eye and optic nerve are an extension of, and therefore a window to, the CNS including their shared vascularization, meningeal coverings, innervation, and CSF spaces. RH has been reported with a variety of conditions including AI, resuscitation, increased intracranial pressure, increased venous pressure, subarachnoid hemorrhage, sepsis, coagulopathy, certain metabolic disorders, systemic hypertension, and other conditions [143,145,153]. The common pathophysiology appears to be increased intracranial pressure or increased intravascular pressure. Furthermore, many cases of RH (and SDH) are confounded by the

sequence or cascade of multiple conditions (e.g. the unified hypothesis of Geddes) that often have a synergistic influence on the type and extent of RH. For example, consider the common situation of a child who has had trauma (factual or assumed) followed by seizures, apnea or respiratory arrest, and resuscitation with resultant HIE or coagulopathy. In much of the traditional NAI / SBS literature, little if any consideration has been given to any predisposing or complicating factors, and often there is no indication of the timing of the eye exams relative to the clinical course or the brain imaging [135,136,141,152].

From the research and clinical evidence base, one may conclude that (1) RH is not specific for NAI, (2) RH may occur in AI and medical conditions, and (3) that predisposing factors and cascade effects must be considered in the pathophysiology of RH.

Medical Conditions Mimicking NAI.

Also a significant part of the controversy are the medical conditions that may mimic the clinical presentations (i.e. the triad) and imaging findings of NAI [7,9,23,31-34,109,121].

Furthermore, such conditions may predispose to, or complicate, AI or NAI, as part of a cascade that results in, or exaggerates, the triad. In some situations it may be difficult, or impossible, to tell which of these elements are “causative” and which are the “effects.” These include HIE, seizures, dysphagic choking ALTE, cardiopulmonary resuscitation, infectious or post infectious

conditions (e.g. sepsis, meningoencephalitis, post-vaccinial), vascular diseases, coagulopathies, venous thrombosis, metabolic disorders, neoplastic processes, certain therapies, extracorporeal membrane oxygenation (ECMO), and other conditions [23,31,109,121]. Regarding pathogenesis of the triad (+/- other organ system involvement - e.g. skeletal), and whether due to NAI, AI, or medical etiologies, the pathophysiology appears to be some combination, or sequence, of factors including increased intracranial pressure, increased venous pressure, systemic hypotension or hypertension, vascular fragility, hematologic derangement, and/or a collagenopathy imposed upon the immature CNS, including the vulnerable dural vascular plexus, as well as other organ systems [23,31,54,55,62].

Although the initial medical evaluation including history, laboratory tests, and imaging studies may suggest an alternative condition, the diagnosis may not be made because of a “rush to judgement” regarding NAI [10-18,23]. Such bias may have devastating effects upon the injured child and family. It is important to be aware of these mimics, since a more extensive workup may be needed beyond the routine “screening” tests. Also, the lack of confirmation of a specific condition does not automatically indicate the “default” diagnosis of NAI. In all cases, it is critical to review all past records dating back to the pregnancy and birth, as well as the postnatal pediatric records, the family history, the more recent history preceding the acute presentation, the details of the acute event itself, the resuscitation, and the

subsequent management, all of which may contribute to the clinical and imaging findings. An incomplete medical evaluation may result in unnecessary cost-shifting to the child protection and criminal justice systems and have further adverse effects regarding transplantation organ donation in brain death cases and custody / adoptive dispositions for the surviving child and siblings.

Sirotnak's recent review, along with others, extensively catalogues the many conditions that may mimic NAI [23,31,109,121]. These include perinatal conditions (birth trauma and congenital conditions), accidental trauma (including dysphagic choking ALTE), genetic and metabolic disorders, hematologic diseases and coagulopathies, infectious diseases, autoimmune and vasculitic conditions, oncologic disease (e.g. neuroblastoma, leukemia), toxins, poisons, and nutritional deficiencies, and medical and surgical complications. A partial summary is provided below.

Birth Trauma and Neonatal Conditions. Manifestations of birth trauma, including fracture, SDH, and RH may persist beyond the neonatal period. Other examples are the sequelae of extracorporeal membrane oxygenation (ECMO) therapy, at-risk prematurity, and congenital heart disease. When evaluating a young infant with apparent NAI, it is important to consider that the clinical and imaging findings may actually stem from parturitional and neonatal issues [93-109]. This includes hemorrhage, or re-hemorrhage, into extracerebral collections existing from birth [Figs 1,4,12,14-16]. There may be associated skeletal findings of birth

trauma (e.g. new or healing clavicle, rib, or long bone fractures), particularly in the presence of a bone fragility disorder [**Figs 2,5**] [**153a – 153c**].

Developmental anomalies and Congenital Conditions. Vascular malformations are rarely reported causes for the triad, but may be underdiagnosed [**Fig.9**]. BECC and arachnoid cysts are also known to be associated with SDH and RH, spontaneously and with trauma [**Figs 4, 14-16**] [**85-94**].

Genetic and Metabolic Disorders. A number of conditions in this category may present with intracranial hemorrhage (e.g. SDH) or RH. These include osteogenesis imperfecta, glutaric aciduria type I [**Fig.13**], Menkes kinky hair disease, Ehlers-Danlos and Marfan syndromes, homocystinuria, and others [**23,109,121,154-158**].

Hematologic Disease and Coagulopathy. Conditions in this category predispose to intracranial hemorrhage and RH [**Figs 11,12**]. The bleeding or clotting disorder may be primary or secondary. A more extensive workup beyond the usual “screening” tests is needed, including a hematology consultation. This includes the anemias, hemorrhagic disease of the newborn (vitamin K deficiency), the hemophilias, thrombophilias, disseminated intravascular coagulation and consumption coagulopathy, liver or kidney disease, hemophagocytic lymphohistiocytosis, and anticoagulant therapy [**23, 109, 121, 159-161**].

Venous thrombosis includes dural venous sinus thrombosis (DVST) and cerebral venous thrombosis (CVT). DVST or CVT may be associated with primary or secondary hematologic or coagulopathic states [23,109,121,161-167]. Risk factors include acute systemic illness, dehydration, fluid-electrolyte imbalance, sepsis, perinatal complications, chronic systemic disease, cardiac disease, connective tissue disorder, hematologic disorder, oncologic disease and therapy, head and neck infection, and hypercoagulable states. Infarction, SAH, SDH, or RH may be seen, especially in infants. High densities on CT may be present along the dural venous sinuses, tentorium, falx, or the cortical, subependymal, or medullary veins and be associated with SAH, SDH, or intracerebral hemorrhage [Fig.8]. There may be focal infarctions, hemorrhagic or nonhemorrhagic, intraventricular hemorrhage, and massive, focal or diffuse edema. Orbit, paranasal sinus, or otomastoid disease may be present. The thromboses and associated hemorrhages have variable MRI appearances depending upon their age. CTV or MRV may readily detect DVST but not CVT. The latter may be better detected as abnormal hypointensities on susceptibility-weighted T2* sequences, but difficult to distinguish from hemorrhage (SDH, SAH), hemorrhagic infarction, contusion, or hemorrhagic shear injury.

Infectious and Post-infectious Conditions. Meningitis, encephalitis, or sepsis may involve the vasculature resulting in vasculitis, arterial or venous thrombosis, mycotic aneurysm, infarction, and hemorrhage [23, 109, 121]. SDH and RH may also be seen

[Fig.10]. Post-infectious illnesses may also be associated with these findings. Included in this category are the “encephalopathies of infancy and childhood”, “hemorrhagic shock and encephalopathy syndrome,” and post-vaccinial encephalopathy **[23,109,121,168-173]**.

Toxins, Poisons, and Nutritional Deficiencies. This category includes lead poisoning, cocaine, anticoagulants, over-the-counter cold medications, prescription drugs, and vitamin deficiencies or depletions (e.g. K, C, D) **[23,109,121,159, 170-175]**. Preterm neonates, and other chronically ill infants, are particularly vulnerable to nutritional deficiencies and complications of prolonged immobilization that often primarily effect bone development. Furthermore, the national and international epidemic of vitamin D deficiency and insufficiency in pregnant mothers, their fetuses, and their undersupplemented breastfed neonates predisposes them to rickets (i.e. congenital). Such infants, whom have also been subjected to the trauma of birth, may have skeletal imaging findings (e.g. multiple healing fractures or pseudofractures) that are misinterpreted as NAI, especially in the presence of the triad **[Figs 2,5] [175]**.

Dysphagic Choking ALTE as a Mimic of NAI. Apnea is an important and common form of ALTE in infancy whose origin may be central, obstructive, or combined **[31]**. The obstructive and mixed forms may present with choking, gasping, coughing, or gagging due to mechanical obstruction. When paroxysmal or

sustained, the result may be severe brain injury or death due to a combination of central venous hypertension and hypoxia-ischemia. It is this synergism that produces cerebral edema and dural vascular plexus hemorrhage with SDH, SAH, and RH [Fig.17]. Examples include dysphagic choking (e.g. aspiration of a feed, gastroesophageal reflux), viral airway infection (e.g. RSV), and pertussis, and particularly when occurring in a predisposed child (e.g. prematurity, Pierre-Robin syndrome, SIDS) [31,176-183].

Imaging Challenges and the Importance of a Differential Diagnosis.

Computed Tomography (CT). Because of the evidence-based challenges to NAI, imaging protocols should be designed to evaluate not only NAI vs. AI, but also the medical mimics. Non-contrast CT has been the primary modality for brain imaging because of its access, speed, and ability to show lesions (e.g. hemorrhage and edema) requiring immediate neurosurgical or medical intervention [23,123,124,128,184-202]. Cervical spinal CT may also be needed. CT angiography or venography (CTA, CTV) may be helpful to evaluate the cause of hemorrhage (e.g. vascular malformation, aneurysm) or infarction (e.g. dissection, venous thrombosis). A radiographic or scintigraphic skeletal survey should also be obtained according to established guidelines (201,202).

Magnetic Resonance Imaging (MRI). Brain and cervical spinal MRI should be done as soon as possible because of its sensitivity and specificity regarding pattern of injury and timing parameters [23,124,128,203-216]. Brain MRI should include T1, T2, T2*, FLAIR, and diffusion imaging (DWI / ADC). Gadolinium-enhanced T1 images should probably be used along with MRA and MRV. T1 and T2 are necessary for estimating the timing of hemorrhage, thrombosis, and other collections using published criteria [23,215,216]. T2* techniques are most sensitive for detecting hemorrhage or thromboses, but may not distinguish new (e.g. deoxyhemoglobin) from old (e.g. hemosiderin). DWI plus ADC can be quickly obtained to show hypoxia-ischemia or vascular occlusive ischemia [23,169,216,217]. However, restricted, or reduced, diffusion may be seen with other processes including encephalitis, seizures, or metabolic disorders, and with suppurative collections and some tumors [23,169,216,217]. Gadolinium-enhanced sequences and MRS can be used to evaluate for these other processes. Additionally, MRA and MRV are important to evaluate for arterial occlusive disease (e.g. dissection) or venous thrombosis, although they cannot rule out small vessel disease. The STIR technique is particularly important for cervical spine imaging.

Scalp and Skull Abnormalities. Scalp injuries (e.g. edema, hemorrhage, laceration) are difficult to precisely time on imaging studies and depend upon the nature and number of traumatic events or other factors (e.g. circulatory compromise, coagulopathy,

medical interventions, etc.) [7,23]. Skull abnormalities may include fracture and suture splitting. Fracture may not be readily distinguished from sutures, synchondroses, their normal variants, or from wormian bones (e.g. osteogenesis imperfecta) on CT or skull films. 3DCT surface reconstructions may be needed. In general, the morphology of a fracture cannot differentiate NAI from AI, and must be correlated with the trauma scenario (e.g. biomechanically) [Fig.1]. Skull fractures are also difficult to time because of the lack of periosteal reaction [7,23]. Suture diastasis may be traumatic or a reflection of increased intracranial pressure, but must be distinguished from pseudodiastasis due to a metabolic or dysplastic bone disorder (e.g. congenital rickets) [Fig.2] [7,23,175,153a-c, 175]. The “growing fracture” (e.g. leptomenigeal cyst” is not specific for NAI and may follow any diastatic fracture in a young infant, including birth-related [Fig.1][7,9,23]. Nondetection of scalp or skull abnormalities on imaging should not be interpreted as the absence of impact injury.

Intracranial Collections. It should not be assumed that such collections are always traumatic in origin. A differential diagnosis is always necessary and includes NAI, AI, coagulopathy (hemophilic and thrombophilic conditions), infectious and post-infectious conditions, metabolic disorders, and so forth [9,23,29,37,109,110,121,126-130]. It may not be possible to specify with any precision the components, or age, of an extracerebral collection because of meningeal disruptions (e.g. acute or subacute subdural hygroma [SDHG] vs. chronic SDH, or

subarachnoid vs. thin subdural hemorrhage)

[7,23,123,124,186,193,197,200a]. Vezina has recently summarized the literature regarding the complexity of timing of intracranial collections [200a]. Subarachnoid and subdural collections, hemorrhagic or nonhemorrhagic, may be localized or extensive, and may occur about the convexities, interhemispheric (along the falx), and along the tentorium. With time and gravity, these collections may redistribute to other areas, including into, or out of, the spinal canal and cause confusion [23, 199,200a,219]. For example, a convexity SDH may migrate to the peritentorial and posterior interhemispheric regions, or into the intraspinal spaces. SDH migration may lead to a misinterpretation that there are hemorrhages of different timing. The distribution, or migration, of the sediment portion of a hemorrhage with blood levels (i.e. hematocrit effect) may cause further confusion since density / intensity differences between the sediment and supernatant may be misinterpreted as hemorrhages (and trauma) of differing age and location [23,124,200-200a]. Prominent subarachnoid cerebrospinal fluid (CSF) spaces are commonly present in infants (i.e. benign extracerebral collections – BECC). This entity predisposes infants to SDH which may be spontaneous or associated with trauma of any type (e.g. dysphagic choking ALTE) [Figs 4,14,16] [23,85-93]. A hemorrhagic collection may continually change, or evolve, with regard to size, extent, location, and density / intensity characteristics. Rapid spontaneous resolution and redistribution of acute SDH over a few hours to 1 - 2 days has been reported

[23,199,220]. A tear in the arachnoid may allow SDH washout into the subarachnoid space or CSF dilution of the subdural space.

For apparent CT high densities, it may be difficult to differentiate cerebral hemorrhage from subarachnoid hemorrhage or from venous thrombosis [Figs 2,3,6-11,14,15,17] [23]. According to the literature, hemorrhage or thromboses that are high density (i.e. clotted) on CT (i.e. acute to subacute) have a wide timing range of 0-3 hours up to 7-10 days [23,124,200,200a]. Hemorrhage that is iso-hypodense on CT (i.e. nonclotted) may be hyperacute (< 3 hrs.) or chronic (> 10 days) [Fig.3,11]. The low density may also represent pre-existing wide CSF-containing subarachnoid spaces (e.g. BECC) or SDHG (i.e. CSF-containing) that may be acute or chronic [Figs 3,13,14] [23, 123,124,197,200a]. Blood levels are unusual in the acute stage unless there is coagulopathy [23,124,215,216]. CT cannot distinguish acute hemorrhage from re-hemorrhage upon existing chronic collections (BECC or chronic SDHG) [Figs 3,14] [23,86,92,99,112-124,193,200,200a]. Traditionally, the interhemispheric SDH as well as mixed density SDH were considered characteristic, if not pathognomonic, of SBS/NAI [7-9,184,190,193]. This has been proven unreliable. In fact, interhemispheric SDH may be seen with AI or with nontraumatic conditions (e.g. HIE, venous thrombosis, venous hypertension, dysphagic choking ALTE) [Figs 2,6-10]. Mixed density SDH also occurs in AI as well as in other conditions [Figs 3,9,11]. Furthermore, SDH may occur in BECC either spontaneously or result from minor trauma (i.e. AI), and

re-hemorrhage within SDH may occur spontaneously or with minor AI [Figs 1,4,14,16] [19,23,54,62,82,110,124,200,200a].

Only MRI may provide more precise information regarding pattern of injury and timing, particularly with regard to (a) hemorrhage vs. thromboses (see Table) and (b) brain injury [23,124,128,203-217]. As a result, MRI has become the standard and should be done as soon as possible. Mixed intensity collections, however, are problematic regarding timing [200a]. Matching the MRI findings with the CT findings may help along with followup MRI. Blood levels may indicate subacute hemorrhage vs. coagulopathy. The timing guidelines are better applied to the sediment than to the supernatant. With mixed intensity collections, MRI cannot reliably differentiate BECC with acute SDH from acute SDHG / SDH, from hyperacute SDH, or from chronic SDH or chronic SDHG with re-hemorrhage [Figs 1,4,12-16] [23,124]. T2* hypointensities are iron-sensitive but may not differentiate hemorrhages from venous thromboses that are not detected by MRV (e.g. cortical, medullary, subependymal).

Brain Injury.

Edema or swelling in pediatric head trauma may represent primary injury or secondary injury and be acute-hyperacute (e.g. minutes to a few hours) or delayed (e.g. several hours to a few days) including association with short falls and lucid interval [23,52-55,74-82].

The edema or swelling may be further subtyped as traumatic,

malignant, hypoxic-ischemic, or related to (or combined with) other factors. Traumatic edema is related to areas of primary brain trauma (i.e. contusion or shear) or to traumatic vascular injury with infarction (e.g. dissection, herniation, spasm) [Figs 3,6,9,11].

Traumatic edema is usually focal or multifocal, whether hemorrhagic or not. However, CT may not distinguish focal or multifocal cerebral high densities as hemorrhagic contusion, hemorrhagic shear, or hemorrhagic infarction (23). Focal or multifocal low density edema may also be seen with infarction (e.g. arterial or venous occlusive), encephalitis, demyelination (e.g. ADEM), or seizure edema [23,109,161-169]. Also, MRI often shows shear and contusional injury as focal / multifocal restricted diffusion, GRE hypointensities, and/or T2 / FLAIR high intensities (23). Focal / multifocal ischemic findings may also be due to traumatic arterial injury (e.g. dissection) or venous injury (e.g. tear, thrombosis), arterial spasm (as with any cause of hemorrhage), herniation, or edema with secondary perfusion deficit or seizures (e.g. status epilepticus) [Figs 1,6,11] [23,84,169,217,218].

However, these may not be reliably differentiated from focal / multifocal ischemic or hemorrhagic infarction from nontraumatic causation (e.g. dissection, vasculitis, venous, embolic) even without supportive MRA, CTA, MRV, or angiography. Also, similar cortical or subcortical intensity abnormalities (including restricted diffusion) may also be observed with encephalitis, seizures, and metabolic disorders. Therefore, a differential diagnosis is always required [23,169,217,218].

Malignant brain edema, a term used for severe cerebral swelling following head trauma, may lead to rapid deterioration [7,23,75,82]. The edema is usually bilateral and may be related to cerebrovascular congestion (i.e. hyperemia) as a vasoreactive rather than an autoregulatory phenomenon and associated with global ischemia. A unilateral form may also occur in association with an ipsilateral SDH that progresses to bilateral edema [Fig.3,6] [84]. There may be rapid or delayed onset (i.e. lucid interval). Predisposing factors are not well-established, but likely include a genetic basis. Hyperemic edema may appear early as accentuated gray-white matter differentiation on CT, then progresses to loss of differentiation.

Global hypoxia (e.g. apnea, respiratory failure) or ischemia (e.g. cardiovascular failure or hypoperfusion) is likely a major cause of, or contributor to, brain edema in the child with head trauma (e.g. malignant edema) [23,52-55,62,75,82]. HIE, depending on its severity and duration, may have a diffuse appearance acutely (i.e. diffuse or “vascular” axonal injury) with decreased gray-white differentiation throughout the cerebrum on CT (e.g. white cerebellum sign), and then evolve to a more specific pattern on CT or MRI (e.g. borderzone or watershed, basal ganglia / thalamic, cerebral white matter necrosis, reversal sign) [Figs 2,6,7,10,17] (23,217) . It is typically bilateral but may not be symmetric. This more diffuse pattern may distinguish HIE from the multifocal pattern of primary traumatic injury, although they may coexist. Hypoxia-ischemic brain injury due to apnea / respiratory arrest

may occur with head trauma or with neck / cervical spine / cord injuries (e.g. SCIWORA) whether AI or NAI [Fig. 7] [23,51-53]. It may also occur with any nontraumatic cause (e.g. choking, paroxysmal coughing, aspiration, etc.) [Figs 2,17] [23, 31,176-182]. In addition to the diffuse brain injury, there may be associated subarachnoid and subdural hemorrhage without mass effect [Figs 2,7,10,17] [23,51-53,62]. MRI shows hypoxic-ischemic injury, depending upon timing, as diffuse restricted diffusion on DWI / ADC plus matching T1/T2 abnormalities as the injury evolves [Figs 2,6] [23,217]. Other important contributors to edema or swelling include such complicating factors as seizures (e.g. status epilepticus [Fig.2]), fluid-electrolyte imbalance, other systemic or metabolic derangements (e.g. hypoglycemia, hyperglycemia, hyperthermia), or hydrocephalus [23]. It is well known that many of these may also be associated with restricted diffusion along with other nontraumatic processes (encephalitis, seizures, and metabolic disorders) [23,169,214,215,217]. Once again, a differential diagnosis is required.

Conclusion

An extensive review of the literature to date fails to establish an evidence base for reliably distinguishing NAI from AI or from the medical mimics. The medical and imaging findings alone cannot diagnose “intentional” injury. Only the child protection investigation may provide the basis for “inflicted” injury in the

context of “supportive” medical, imaging, or pathologic data. The duty of the radiologist is to give a detailed description of the imaging findings, provide a differential diagnosis, and communicate the concern for NAI, directly to the primary care team in a timely manner. The radiologist should be prepared to consult with child protection services, other medical and surgical consultants, including the pathologist or biomechanical specialist, law enforcement investigators, and attorneys for all parties as appropriate. The radiologist must also be aware of certain conditions that are known to have clinical and imaging features that may mimic abuse. These should be properly evaluated, and the possibility of combined, or multifactorial, mechanisms with synergistic effects should also be considered. Furthermore, a negative medical evaluation does not make NAI the default diagnosis. A timely and thorough multidisciplinary evaluation may be the difference between appropriate child protection versus an improper breakup of the family or a wrongful indictment and conviction.

References

1. Harding B, Risdon RA, Krous HF. Shaken baby syndrome (editorial). *BMJ* 2004; 328:720.
2. American Academy of Pediatrics Committee on Child Abuse and Neglect. Shaken baby syndrome: inflicted cerebral trauma. *Pediatrics* 1993; 92:872-875).
3. Caffey J. Multiple fractures in the long bones of infants suffering from chronic subdural hematoma. *Am J Roentgenol* 1946; 56: 163-173.
4. Kempe C, Silverman F, et al. The battered child syndrome *JAMA* 1962; 181: 17-24.

5. Guthkelch A. Infantile subdural haematoma and its relationship to whiplash injuries. *BMJ* 1971; 2: 430-431.
6. Caffey J. On the theory and practice of shaking infants. *Am J Dis Child* 1972; 124: 161-169.
7. Kleinman P. *Diagnostic Imaging of Child Abuse*, Mosby Year Book, New York, 1998.
8. Lonergan G, et al. From the Archives of the AFIP. Child abuse: radiologic-pathologic correlation. *RadioGraphics* 2003;23:811-845.
9. Frasier L et al, *Abusive Head Trauma in Infants and Children*, GW Medical Publishing, St. Louis, 2006.
10. Donohoe M. Evidence-based medicine and shaken baby syndrome part I: literature review, 1966-1998. *Am J Forensic Med Pathol* 2003;24:239-42.
11. Leestma J. Case analysis of brain injured admittedly shaken infants, 54 cases 1969-2001. *Am J Forensic Med Pathol* 2005: 26:199-212.
12. Lyons. Shaken Baby Syndrome: A Questionable Scientific Syndrome and a Dangerous Legal Concept. *Utah Law Rev* 2003;1109.
13. Gena M. Shaken baby syndrome: medical uncertainty casts doubt on convictions. *Wisc Law Rev* 2007;701.
14. Goudge Hon ST. Report of the inquiry into pediatric forensic pathology in Ontario. Ontario Ministry of the Attorney General. Queen's Printer for Ontario, September 30, 2008. www.goudgeinquiry.ca.
15. Le Fanu J. Wrongful diagnosis of child abuse – a master theory. *J R Soc Med* 2006;98:249-254.
16. Mackey M. After the Court of Appeal: *R v Harris and others* [2005] EWCA crim 1980. *Arch Dis Child* 2006;91:873-875.
17. Richards P, Bertocci G, Bonshek R, et al. Shaken baby syndrome. Before the Court of Appeal. *Arch Dis Child* 2006;91:205-206.
- 17a. Tuerkheimer D. The next innocence project: shaken baby syndrome and the criminal courts. *Wash U L Rev* 2009;87: in press, Sept. 2009.
18. Baath J. Shaken baby syndrome: the debate rages on. *U. Toronto Med J* 2005;83:22-23.

19. Squier W. Shaken baby syndrome: the quest for evidence. *Develop Med Child Neurol* 2008;50:10-14.
20. Gilliland MGF 2006. Use of the triad of scant SDH, brain swelling, and retinal hemorrhages to diagnose non-accidental injury is not scientifically valid. Abstract # 53. National Association of Medical Examiners Annual Meeting, Oct. 2006.
21. David TJ. Non-accidental head injury – the evidence. *Pediatr Radiol* 2008;38 (Suppl 3): S370-S377.
22. Jaspan T. Current controversies in the interpretation of non-accidental head injury. *Pediatr Radiol* 2008;38: (Suppl 3): S378-387.
23. Barnes P, Krasnokutsky M. Imaging of the CNS in Suspected or Alleged NAI. *Topics Magn Res Imag* 2007;18:53-74.
24. Guyatt et al. Users' guides to the medical literature. XXV. Evidence-based medicine. *JAMA* 2000;284:1290-1296;
25. Collins J. Evidence-based medicine. *J Am Coll Radiol* 2007;4(8):551-554.
26. Blackmore C, Medina LS. Evidence-based radiology and the ACR appropriateness criteria. *J Am Coll Radiol* 2006;3(7):505-509.
27. Crosskerry P. The importance of cognitive errors in diagnosis and strategies to minimize them. *Acad Med* 2003;78:775-780.
- 27a. Newman, DH. Physician says medical ideology “gets in the way” of evidence-based medicine. *New York Times* 4-2-09; *AMA News* 4-3-09.
- 27b. Groopman J, Hartzband P. Why ‘quality care’ is dangerous. *The Wall Street Journal*. *WSJ.com*. 4-8-09.
28. Feldman K, Bethel R, Shugerman P, et al. The cause of infant and toddler subdural hemorrhage: a prospective study. *Pediatrics* 2001;108:636-646.
29. Hobbs C, Childs A, Wynne J, et al. Subdural haematoma and effusion in infancy: an epidemiological study. *Arch Dis Child* 2005;90:952-955.
30. Keierleber J, Bohan T. Ten years after Daubert: the status of the states. *J Forensic Sci* 2005;50:1-10.
31. DeWolfe CC. Apparent life-threatening event: a review. *Pediatr Clin N Am* 2005;52:1127-1146.
32. Altman R, Brand D, Forman S, et al. Abusive Head Injury as a Cause of Apparent Life-Threatening Events in Infancy. *Arch Pediatr Adolesc Med* 2003;157:1011-1015.

33. Brand D, Altman R, Purtill K, Edwards K. Yield of diagnostic testing in infants who have had an apparent life-threatening event. *Pediatrics* 2005;115:885-893.
34. Bonkowsky J, Guenther E, Filoux F, Srivastava R. Death, child abuse, and adverse neurological outcome of infants after an apparent life-threatening event. *Pediatrics* 2008;122:125-131.
35. Caffey J. The whiplash shaken infant syndrome: manual shaking by the extremities with whiplash-induced intracranial and intraocular bleedings, linked with residual permanent brain damage and mental retardation. *Pediatrics* 1974;54: 1.
36. Ommaya A. Whiplash injury and brain damage. *JAMA* 1968; 204: 75-79.
37. Uscinski R. Shaken baby syndrome: fundamental questions. *Brit J Neurosurg* 2002;16:217-219.
38. Uscinski R. Shaken baby syndrome: an odyssey. *Neurol Med Chir (Tokyo)* 2006;46:57-61.
39. Uscinski R, McBride D. The shaken baby syndrome: an odyssey – II – origins and further hypotheses. *Neurol Med Chir (Tokyo)* 2008; 48: 151-156.
40. Duhaime A, Gennerelli T, Thibault L, et al. The shaken baby syndrome. A clinical, pathological, and biomechanical study. *J Neurosurg* 1987; 66:409-415.
41. Prange M, Coats B, Duhaime A, Margulis S. Anthropomorphic simulations of falls, shakes, and inflicted impacts in infants. *J. Neurosurg.* 2003;99:143-150.
- 41a. Van Ee C. In, Leestma J. *Forensic Neuropathology*, 2nd Ed, CRC Press, Boca Raton FL, 2009, p. 603.
42. Ommaya A, Goldsmith W, Thibault L. Biomechanics and neuropathology of adult and paediatric head injury. *British J Neurosurg* 2002; 16: 220-242.
43. Goldsmith W, Plunkett J. Biomechanical analysis of the causes of traumatic brain injury in infants and children. *Am J Forensic Med Pathol* 2004;25:89-100.
44. Cory CZ, Jones MD. Can shaking alone cause fatal brain injury? A biomechanical assessment of the Duhaime shaken baby syndrome model. *Med Sci Law* 2003; 43: 317.
- 44a. Coats B, Margulies S. Potential for head injuries in infants from low-height falls. *J Neurosurg Pediatrics* 2008;2:321-330.
45. Bandak FA. Shaken baby syndrome: a biomechanics analysis of injury mechanisms. *Forensic Sci Int.* 2005; 151:71-79.

- 45a. Margulies S, Prange M, Myers B, et al. Shaken baby syndrome: a flawed biomechanical analysis. *Forensic Sci Int* 2006;164:278-279.
- 45b. Bandak FA. Response to the Letter to the Editor. *Forensic Sci Int* 2006;164:282-283.
46. Ouyang J, Zhu Q, Zhao W, Xu Y, Chen W, Zhong S. Biomechanical assessment of the pediatric cervical spine under bending and tensile loading. *Spine*. 2005;30(24):E716-23.
47. Luck JF, Prange M, Nightingale RW, Loyd A, Dibb A, Ottaviano D, Tran L, Myers BS. Tensile mechanical properties of the pediatric human osteoligamentous cervical spine. *Injury & Orthopaedic Biomechanics Research Laboratory, Department of Biomedical Engineering, Duke University, Durham, NC, USA. (5979 5.3 Spine Kinematics and Injury Biomechanics S151).*
48. Prange M, Newberry W, Moore T et al. Inertial neck injuries in children involved in frontal collisions. *Society of Automotive Engineers SAE International* 2007 -01-1170.
49. Pierce MC, Bertocci G. Injury biomechanics and child abuse. *Annu. Rev. Biomed. Eng.* 2008;10:85-106.
50. Roth S, Raul J-S, Ludes B, Willinger R. Finite element analysis of impact and shaking inflicted to a child. *Int J Legal Med* 2006.
51. Barnes P, Krasnokutsky M, Monson K, Ophoven J. Traumatic spinal cord injury: accidental vs. nonaccidental injury. *Semin Pediatr Neurol* 2008;15:178-184.
52. Geddes J, Hackshaw A, Vowles G et al. Neuropathology of Inflicted Head Injury in Children. I. Pattern of Brain Injury. *Brain* 2001; 124: 1290-1298.
53. Geddes J, Vowles G, Hackshaw A, et al. Neuropathology of Inflicted Head Injury in Children. II. Microscopic Brain injury in Infants. *Brain* 2001; 124: 1299-1306.
54. Geddes J, Tasker R, Hackshaw A, et al. Dural Haemorrhage in Non-traumatic Infant Deaths: Does it Explain the Bleeding in 'Shaken Baby Syndrome'? *Neuropathology and Applied Neurobiology* 2003; 29: 14-22.
55. Geddes J, Whitwell H. Inflicted head injury in infants. *Forensic Science International* 2004;146:83-88.
56. Punt J, Bonshek, R, Jaspan T, et al. The 'unified hypothesis' of Geddes et al. is not supported by the data. *Pediatric Rehabilitation* 2004;7:173-184.
57. Minns R. Shaken baby syndrome: theoretical and evidential controversies. *J R Coll Physicians Edinb* 2005;35:5-15.

58. Byard R, Blumbergs P, Ruttly G, et al. Lack of evidence for a causal relationship between hypoxic-ischemic encephalopathy and subdural hemorrhage in fetal life, infancy, and early childhood. *Ped Develop Pathol* 2007;10:348-350.
59. Hauser R, Jankowski Z, Gos T, Krzyżanowski M. Hemorrhages in head tissues during the asphyxiation process. *Forens Sc Int* 2001; 124:235-236.
60. Kibayashi K, Shojo H and Sumida T. Dural hemorrhage of the tentorium on postmortem cranial tomographic scans in children. *Forensic Sci Int* 2005; 154:206-9.
61. Cohen M, Cox P, Kiho L, et al. "Lack of evidence for a causal relationship between hypoxic ischemic encephalopathy and subdural hemorrhage in fetal life, infancy and early childhood". Byard et al. A response. *Ped Develop Pathol* 2007;10 :500-501.
62. Cohen M, Scheimberg I. Evidence of occurrence of intradural and subdural hemorrhage in the perinatal and neonatal period in the context of hypoxic ischemic encephalopathy. *Pediatr Develop Pathol* 2009;12:169-176.
- 62a. Cohen M, Scheimbert I. Histology of the dural membrane supports the theoretical considerations of its role in the pathophysiology of subdural collections in nontraumatic circumstances. *Pediatr Radiol* 2009;39:880-881.
- 62b. Croft P, Reichard R. Microscopic examination of grossly unremarkable pediatric dura mater. *Am J Forensic Med Pathol* 2009;30:10-13.
63. Koto T, Takubo K, Ishida S, et al. Hypoxia disrupts the barrier function of neural blood vessels through changes in the expression of claudin -5 endothelial cells. *Am J Pathol* 2007; 170:446 1389-1397.
64. Emerson M, Pieramici D, Stoessel K, et al. Incidence and rate of disappearance of retinal hemorrhage in newborns. *Ophthalmology* 2001;108: 36-39.
65. Hall J, Reyes H, Horvat M, et al. The mortality of childhood falls. *J Trauma* 1989;29:1273-1275.
66. Chadwick D et al. Deaths from falls in children: How far is fatal. *J Trauma* 1991;31: 1335.
67. Helfer R, Slovis T, Black M. Injuries resulting when small children fall out of bed. *Pediatrics* 1977;60:533-535.
68. Reiber G. Fatal falls in childhood. *Am J Forensic Med Pathol* 1993;14:201-207.

69. Williams R. Injuries in infants and small children resulting from witnessed and corroborated free falls. *J Trauma* 1991;31:1350-1352.
70. Lyons T, Oates R. Falling out of bed: a relatively benign occurrence. *Pediatrics* 1993;92:125-127.
71. Oehmichen M, Meissner C, Saternus K. Fall or shaken: traumatic brain injury in children caused by falls or abuse at home – a review on biomechanics and diagnosis. *Neuropediatrics* 2005;36:240-245.
72. Duhaime A, Alario A, Lewander W, et al. Head injury in very young children: Mechanisms, injury types, and ophthalmologic findings in 100 hospitalized patients younger than 2 years of age. *Pediatrics* 1992;90:179-185.
73. Schutzman SA, Barnes PD, Duhaime A-C, et al. Evaluation and management of children younger than two years old with apparently minor head trauma: proposed guidelines. *Pediatrics* 2001; 107: 983-993.
74. Stein S, Spettell C: Delayed and progressive brain injury in children and adolescents with head trauma *Pediatr. Neurosurg.* 1995; 23, 299-304.
75. Bruce D. Delayed deterioration of consciousness after trivial head injury in childhood. *Br Med J (Clin Res Ed).* 1984;289:715-716.
- 75a. Bruce D, Alavi A, Bilaniuk L, et al. Diffuse cerebral swelling following head injuries in children: the syndrome of “malignant brain edema.” *J Neurosurg* 1981;54:170-178.
76. Plunkett J. Fatal Pediatric Head Injuries Caused by Short-Distance Falls. *Am J Forensic Med Pathol* 2001; 22: 1-12 (18 cases, 2-10 feet).
77. Greenes D, Schutzman S. Occult intracranial trauma in infants. *Ann Emerg Med* 1998; 32: 680-686 (19 infants, 2 feet-9 stairs).
78. Arbogast K, Margulis S, Christian C. Initial neurologic presentation in young children sustaining inflicted and unintentional fatal head injuries. *Pediatrics* 2005; 116: 180-184.
79. Denton S, Mileusnic D. Delayed sudden death in an infant following an accidental fall. *Am J Forensic Med Pathol* 2003;24:371-376.
80. Murray J, Chen D, Velmahos G, et al. Pediatric falls: is height a predictor of injury and outcome? *The American Surgeon* 2000; 66: 863-865.
81. Kim K, Wang M, Griffith P et al. Analysis of pediatric head injury falls. *Neurosurg Focus* 2000;8:1-9.

82. Steinbok P, Singhal A, Poskitt K, Cochrane D. Early hypodensity on CT scan of the brain in accidental pediatric head injury. *Neurosurgery* 2007;60:689-695.
83. Christian CW, Taylor AA, Hertle RW, Duhaime A-C. Retinal hemorrhages caused by accidental household trauma. *J Pediatr* 1999; 135: 125-127.
84. Durham SR, Duhaime A-C. Maturation-dependent response of the immature brain to experimental subdural hematoma. *J Neurotrauma* 2007;24:5-14.
85. Azais M, Echenne B. Idiopathic pericerebral effusions of infancy (external hydrocephalus). *Annales Pediatr (Paris)* 1992;39:550-558.
86. Piatt J. A Pitfall in the Diagnosis of Child Abuse: External Hydrocephalus, Subdural Hematoma, and Retinal Hemorrhages. *Neurosurg Focus* 1999; 7(4): 1-8.
87. Pittman T. Significance of subdural hematoma in a child with external hydrocephalus. *Pediatric Neurosurgery* 2003; 39: 57-59.
88. Papasian N, Frim D. A theoretical model of benign external hydrocephalus that predicts a predisposition towards extra-axial hemorrhage after minor head trauma. *Pediatr Neurosurg* 2000; 33: 188-193.
89. Hangique S, Das R, Barua N, et al. External hydrocephalus in children. *Ind J Radiol Imag* 2002;12:197-200.
90. Mori K, Sakamoto T, Mishimura K, Fujiwara K. Subarachnoid fluid collection in infants complicated by subdural hematoma. *Childs Nerv Syst* 1993;9:282-284.
91. Ravid S, Maytal J. External hydrocephalus: a probable cause for subdural hematoma of infancy. *Pediatr Neurol* 2003;28:139-141.
92. McNeely PD, Atkinson JD, Saigal G, O’Gorman AM, Farmer J-P. Subdural hematomas in infants with benign enlargement of the subarachnoid spaces are not pathognomonic for child abuse. *Am J Neuroradiol* 2006; 27:1725-1728.
93. Hellbusch L. Benign extracerebral fluid collections in infancy: clinical presentation and long-term follow-up. *J Neurosurg* 2007;107:119-117.
94. Mori K, Yamamoto T, Horinaka N, Maeda M. Arachnoid cyst is a risk factor for chronic subdural hematoma in juveniles. *J Neurotrauma* 2002;19:1017-1027.
95. Holden K et al. Cranial MRI of normal term neonates: a pilot study. *J Child Neurol* 1999;14:708-710 (50%).
96. Chamnanvanakij S, Rollins N, Perlman J. Subdural hematoma in term infants. *Pediatr Neurol* 2002;26:301-304.

97. Whitby E, Griffiths P, Rutter S, et al. Frequency and natural history of subdural hemorrhages in babies and relation to obstetric factors. *Lancet* 2004;363:846-851 (8%).
98. Looney C, Smith J, Merck L, et al. Intracranial hemorrhage in asymptomatic neonates: prevalence on MRI and relationship to obstetric and neonatal risk factors. *Radiology* 2007; 242: 535-541 (26%).
99. Rooks V, Eaton J, Ruess L et al. Prevalence and evolution of intracranial hemorrhage in asymptomatic term infants. *AJNR*, April 2008 (46%).
100. Volpe JJ. *Neurology of the newborn*. 4th ed. Philadelphia, PA. WB Saunders, 2000.
101. Ney J, Joseph K, Mitchell M. Late subdural hygromas from birth trauma. *Neurology* 2005;65:517.
102. Powers C, Fuchs H, George T. Chronic subdural hematoma of the neonate. *Pediatr Neurosurg* 2007;43:25-28.
103. Hayashi T, Hashimoto T, Fukuda S, et al. Neonatal subdural hematoma secondary to birth injury. *Child's Nerv Syst* 1987; 3:23-29.
104. Ross M, Fresquez M, El-Hacklad M. Impact of FDA advisory on reported vacuum-assisted delivery and morbidity. *J Matern-Fetal Med* 2000;9:321-326.
105. Towner D, Castro M, Eby-Wilkens E, Gilbert W. Effect of mode of delivery in nulliparous women on neonatal intracranial injury. *N Engl J Med* 1999;341:1709-1714.
106. Polina J, Dias M, Kachurek D, Arbesman M. Cranial birth injuries in term newborn infants. *Pediatr Neurosurg* 35:113-119.
107. Alexander J, Leveno K, Hauth J, et al. Fetal injury associated with cesarean delivery. *Obstet Gynecol* 2006;108:885-890.
108. Doumouchtsis S, Arulkumaran S. Head trauma after instrumental births. *Clin Perinatol* 2008;35:69-83.
109. Sirotnak, A. Medical disorders that mimic abusive head trauma. In: Frasier L, et al, eds. *Abusive head trauma in infants and children*. St. Louis, MO. GW Medical Publishing, 2006.
110. Mack J, Squier W, Eastman J. Anatomy and development of the meninges: implications for subdural collections and cerebrospinal fluid circulation. *Pediatr Radiology* 2009;39:200-210.
111. Haines D, Harkey H, Al-Mefty O. The subdural space: a new look at an outdated concept. *Neurosurg* 1993;32:111-120.

112. Kawakami Y, et al. Coagulation and fibrinolysis in chronic subdural hematoma. *Neurosurgery* 1998; 25: 25-29.
113. Murakami H, Hirose Y, Sagoh M, et al. Why do chronic subdura hematomas continue to grow slowly and not coagulate? *J Neurosurg* 2002;96:877-884.
114. Parent AD. Pediatric chronic subdural hematoma. A retrospective comparative analysis. *Pediatric Neurosurgery* 1992; 18:266-271.
115. Hwang S, Kim S. Infantile Head Injury, with Special Reference to the Development of Chronic Subdural Hematoma. *Child's Nerv Syst* 2000; 16: 590-594.
116. Fung E et al. Unexplained Subdural Hematoma in Young Children: Is it always Child Abuse. *Pediatrics International* 2002; 44: 37-42.
117. Aoki N, Masuzawa H. Infantile acute subdural hematoma: *J Neurosurgery* 1984; 61: 273-280.
118. Aoki N. Chronic subdural hematoma in infancy. *J Neurosurg* 1990;73:201-205.
119. Ikeda A, Sato O, Tsugane R, et al. Infantile acute subdural hematoma. *Child's Nerv Syst* 1987;3:19-22.
120. Dyer O. Brain Haemorrhage in Babies may not Indicate Violent Abuse. *BMJ* 2003; 326; 616.
121. Hymel K, Jenny C, Block R. Intracranial hemorrhage and rebleeding in suspected victims of abusive head trauma: addressing the forensic controversies. *Child Maltreatment* 2002; 7: 329-348.
122. Howard M, Bell B, Uttley D. The pathophysiology of infant subdural haematomas. *Brit J Neurosurg* 1993;7:355-365.
123. Vinchon M, Noizet O, Defoort-Dhellemmes S, et al. Infantile subdural hematomas due to traffic accidents. *Pediatr Neurosurg* 2002;37:245-253.
124. Vinchon M, Noule N, Tchofo P, et al. Imaging of head injuries in infants: temporal correlates and forensic implications for the diagnosis of child abuse. *J Neurosurg (Pediatrics 2)* 2004;101:44-52.
125. Maxeiner H. Demonstration and interpretation of bridging vein ruptures in cases of infantile subdural bleeding. *J Forensic Sci* 2001;46:85-93.
126. Minns R. Subdural haemorrhages, haematomas, and effusions of infancy. *Arch Dis Child* 2005;90:883-884.

127. Hobbs C, Childs A, Wynne J, et al. Subdural haematoma and effusion in infancy. *Arch Dis Child* 2005;90:952-955.
128. Datta S, Stoodley N, Jayawant S, et al. Neuroradiological aspects of subdural haemorrhages. *Arch Dis Child* 2005;90:947-951.
129. Kemp A. Investigating subdural haemorrhage in infants. *Arch Dis Child* 2002;86:98-102.
130. Jayawant S, Rawlinson A, Gibbon F, et al. Subdural haemorrhages in infants: population based study. *BMJ* 1998;317:1558-1561.
131. Jayawant S, Parr J. Outcome following subdural haemorrhages in infancy. *Arch Dis Child* 2007;92:343-347.
132. Trenchs V, Curcoy A, Navarro R, Pou J. Subdural haematomas and physical abuse in the first two years of life. *Pediatr Neurosurg* 2007;43:352-357.
133. Powers C, Fuchs H, George T. Chronic subdural hematoma of the neonate. *Pediatr Neurosurg* 2007;43:25-28.
134. Kellogg N, COCAN. Evaluation of suspected child physical abuse. *Pediatrics* 2007;119:1232-1241.
135. Galaznik J. Eye findings and allegations of shaking and non-accidental injury: post-publication peer review (8 August 2007). *Pediatrics* 2007;119:1232-1241.
136. Galaznik J. Shaken baby syndrome: letter to the editor. *Developmental Medicine & Child Neurology* 2008;50: 317-319.
137. Levin A, Wagnanski-Jaffe T, Shafiq A, et al. Postmortem orbital findings in shaken baby syndrome. *Am J Ophthalmol* 2006;142:233-240.
138. Morad Y, Kim Y, Armstrong D, et al. Correlation between retinal abnormalities and intracranial abnormalities in the shaken baby syndrome. *Am J Ophthalmol* 2002;134:354-359.
139. Kirshner R, Stein R. The mistaken diagnosis of child abuse. A form of medical abuse? *Am J Dis Child* 1985; 139: 873-875.
140. Tongue A. The ophthalmologists role in diagnosing child abuse. *Ophthalmology* 1991;98:1009-1010.
141. Gardner H. Correlation between retinal abnormalities and intracranial abnormalities in the shaken baby syndrome. *Am J Ophthalmology* 2003; 135: 745-746.

142. Gilles E, McGregor M, Levy-Clarke G. Retinal hemorrhage asymmetry in inflicted head injury: a clue to pathogenesis? *J Pediatr* 2003;143:494-499.
143. Gilliland M, Luthert P. Why do histology on retinal hemorrhages in suspected nonaccidental injury. *Histopathology* 2003; 43:592-602.
144. Lantz P, Sinal S, Staton C, Weaver Jr R. Perimacular retinal folds from childhood head trauma: evidence-based case report. *BMJ* 2004; 328: 754-756.
145. Aryan H, Ghosheh F, Jandial R, Levy M. Retinal hemorrhage and pediatric brain injury: etiology and review of the literature. *J Clin Neuroscience* 2005; 12:624-631.
146. Lueder G et al. Perimacular retinal folds simulating nonaccidental injury in an infant. *Arch Ophthalmol* 2006;124:1782-1783.
147. Obi E, Watts P. Are there any pathognomonic signs in shaken baby syndrome. *J AAPOS* 2007; 11:99-100.
148. Forbes B, Cox M, Christian C. Retinal hemorrhages in patients with epidural hematomas. *J AAPOS* 2008;12:177-180.
149. Binenaum G, Forbes B, Raghupathi R, et al . An animal model to study retinal hemorrhages in nonimpact brain injury. *J AAPOS* 2007;11:84-85.
150. Brown S, Levin A, Ramsey D, Serbanescu I. Natural animal shaking: a model for inflicted neurotrauma in children? *J AAPOS* 2007;11:85-86.
151. Emerson M et al. Ocular autopsy and histopathologic features of child abuse. *Ophthalmology* 2007;114:1384-1394.
152. Gardner H. Retinal folds. *Arch Ophthalmology* 2007;125:1142.
153. Lantz PE. Postmortem detection and evaluation of retinal hemorrhages. Abstract G104. American Academy of Forensic Sciences, 2006.
- 153a. 219. Jenny C et al. [AAP COCAN]. Evaluating infants and young children with multiple fractures. *Pediatrics* 2006;118: 1299-1303.
- 153b. 220. Bishop N et al. Unexplained fractures in infancy: looking for fragile bones. *Arch Dis Child* 2007;92:251-256.
- 153c. 221. Kleinman P. Problems in the diagnosis of metaphyseal fractures. *Pediatr Radiol* 2008;38 (Suppl. 3): S388-S394.

154. Ganesh A, Jenny C, Geyer J, et al. Retinal hemorrhages in type I osteogenesis imperfecta after minor trauma. *Ophthalmology* 2004;111:1428-1431.
155. Groninger A, Schaper J, Messing-Juenger M, et al. Subdural hematoma as clinical presentation of osteogenesis imperfecta. *Pediatr Neurol* 2005;32:140-142.
156. Strauss K, Puffenberger E, Robinson D, Morton D. Type I glutaric aciduria, part 1: natural history of 77 patients. *Semin Med Genet* 2003;121C:38-52.
157. Nassogne M-C, Sharrad M, Hertz-Pannier L, et al. Massive subdural haematomas in Menkes disease mimicking shaken baby syndrome. *Childs Nerv Syst* 2002;18:729-731.
158. Ernst L, Sondheimer N, Deardorff M, et al. The value of the metabolic autopsy in the pediatric hospital setting. *J Pediatr* 2006;148:779-783.
159. Brousseau T, Kissoon N, McIntosh B. Vitamin K deficiency mimicking child abuse. *J Emerg Med* 2005;29:283-288.
160. Rooms L, Fitzgerald N, McClain KL. Hemophagocytic lymphohistiocytosis masquerading as child abuse. *Pediatrics* 2003;111:636-640.
- 160a. Liesner R, Hann I, Khair K. Non-accidental injury and the haematologist: the causes and investigation of easy bruising. *Blood Coagulation and Fibrinolysis* 2004;15 (suppl 1): S41-S48.
161. Roach E, Golomb M, Adams R, et al. Management of stroke in infants and children. *Stroke* 2008;39:2644-2691.
162. Carvalho KS, Bodensteiner JB, Connolly PJ, Garg BP. Cerebral venous thrombosis in children. *J Child Neurology* 2001;16:574-585.
163. Fitzgerald KC, Williams LS, Garg BP, et al. Cerebral sinovenous thrombosis in the neonate. *Arch Neurol* 2006;63:405-409.
164. DeVeber G, Andrew M, Group CPISS. Cerebral sinovenous thrombosis in children. *N Engl J Med* 2001;345:417-423.
165. Barnes C, deVeber G. Prothrombotic abnormalities in childhood ischaemic stroke. *Thrombosis Research* 2006;118:67-74.
166. Sebire G, Tabarki B, Saunders D, et al. Cerebral venous sinus thrombosis in children: risk factors, presentation, diagnosis, and outcome. *Brain* 2005;128:477-489.
167. Krasnokutsky M, Barnes P. Cerebral Venous Thrombosis: a mimic of nonaccidental injury. Scientific Paper Session. Society for Pediatric Radiology. Miami FL. April 18, 2007.

168. Menge T, Hemmer B, Nessler S, et al. Acute disseminated encephalomyelitis. An update. *Arch Neurol* 2005;62:1673-1680.
169. Moritani T, Smoker W, Sato Y, et al. Diffusion-weighted imaging of acute excitotoxic brain injury. *AJNR Am J Neuroradiol* 2005;26:216-228.
170. Yazbak F. Multiple vaccinations and the shaken baby syndrome. National Vaccine Information Center. The Vaccine Adverse Event Reporting System (VAERS) of the Center for Disease Control and Prevention (CDC) and the Food and Drug Administration (FDA), www.nvic.org/doctors_corner/ed_yazbak_shaken-baby_syndrome.htm.
171. Innis M. Vaccines, apparent life-threatening events, Barlow's disease, and questions about "Shaken baby syndrome." *J American Physicians and Surgeons* 2006;11: 17-19.
172. Clemetson CAB. Is it "shaken baby," or Barlow's disease variant? *J American Physicians and Surgeons* 2004;9:78-80.
173. Clemetson CAB. Caffey revisited: a commentary on the origin of "shaken baby syndrome." *J American Physicians and Surgeons* 2006;11:20-21.
174. Marinetti L, Lehman L, Casto B, et al. Over-the-counter cold medications – postmortem findings in infants and the relationship to cause of death. *J Analytical Toxicology* 2005;29:738-743.
175. Keller K, Barnes P. Rickets vs. abuse: a national and international epidemic. *Pediatr Radiol* 2008;38:1210-1216.
176. Geddes J, Talbert D. Paroxysmal coughing, subdural, and retinal bleeding: a computer modeling approach. *Neuropathol Appl Neurobiol* 2006;32:625-634.
177. Talbert D. The sutured skull and intracranial bleeding in infants. *Med. Hypotheses*. 2006; 66:691-694.
178. American Academy of Pediatrics red book online. Pertussis. <http://www.aapredbook.aappublications.org/cgi/content/full/2003/1/3.9> 2003:472.
179. SurrIDGE J, Segedin E, Grant C. Pertussis requiring intensive care. *Arch Dis Child* 2007;92:970-975.
180. CDC National Immunization Program. General pertussis information <http://www.cdc.gov/doc.do/id/0900f3ec80228696> 2000:2.
181. Page M, Jeffery H. The role of gastro-oesophageal reflux in the aetiology of SIDS. *Early Hum Dev* 2000;59:127-49.

182. Mohan P. Aspiration in infants and children. *Pediatr Rev* 2002;23:330-1.
183. Barnes P, Galaznik J, Krasnokutsky M, et al. CT in Infant Dysphagic Choking Acute Life Threatening Event (ALTE – a mimic of child abuse). Scientific Session, Society for Pediatric Radiology, Scottsdale AZ, May 2008.
184. Zimmerman RA, Bilaniuk LT, Bruce D, et al. Interhemispheric acute subdural hematoma. A computed tomographic manifestation of child abuse by shaking. *Neuroradiology* 1979; 16:39-40.
185. Merten DF, Osborne DRS, Radkowski MA, Leonidas JC. Craniocerebral trauma in the child abuse syndrome: radiological observations. *Pediatr Radiol* 1984; 14: 272-277.
186. Greenberg J, Dohen WA, Cooper PR. The hyperacute extra-axial intracranial hematoma: computed tomographic findings and clinical significance. *Neurosurg* 1985; 17(1): 48-56.
187. Cohen RA, Kaufman RA, Myers PA, Towbin RB. Cranial computed tomography in the abused child with head injury. *AJNR* 1985; 6: 883-888.
188. Bird CR, McMahan JR, Gilles RH, et al. Strangulation in child abuse: CT diagnosis. *Radiology* 1987; 163: 373-375.
189. Mogbo KI, Slovis TL, Canady AI, et al. Appropriate imaging in children with skull fractures and suspicion of abuse, *Radiology* 1998; 208: 521-524.
190. Hymal KP, Rumack CM, Hay TC, et al. Comparison of intracranial CT findings in pediatric abusive and accidental head trauma, *Pediatr Radiol* 1997; 27:743-747.
191. Dias MS, Backstrom J, Falk M, Li V. Serial radiography in the infant shaken impact syndrome. *Pediatr Neurosurg.* 1998; 29: 77-85.
192. Ewings-Cobbs L, Prasad M, Kramer L, et al. Acute neuroradiologic findings in young children with inflicted or noninflicted traumatic brain injury. *Child Nerv Syst.* 2000; 16: 25-33.
193. Barnes PD, Robson CD. CT findings in hyperacute nonaccidental brain injury. *Pediatr Radiol* 2000; 30: 74-81.
194. Rao P, Carty H, Pierce A. The acute reversal sign: comparison of medical and nonaccidental injury patients. *Clin Radiol* 1999; 54: 495-501.
195. . Rubin D, Christian C, Bilaniuk L, et al. Occult head injury in high-risk abused children. *Pediatrics* 2003;111:1382-1386.
196. Wells R, Vetter C, Laud P. Intracranial hemorrhage in children younger than 3 years. *Arch Pediatr Adolesc Med* 2002;156:252-257.

197. Wells R, Sty J. Traumatic low attenuation subdural fluid collections in children younger than 3 years. *Arch Pediatr Adolesc Med* 2003; 157:1005-1010.
198. Stoodley N. Neuroimaging in non-accidental head injury: if, when, why and how. *Clinical Radiology* 2005;60:22-30.
199. Duhaime AC, Christian C, Armonda R, et al. Disappearing subdural hematomas in children. *Pediatr Neurosurg*. 1996 Sep;25(3):116-22.
200. Tung GA, Kumar M, Richardson RC, Jenny C, Brown WD. Comparison of accidental and nonaccidental traumatic head injury in children on noncontrast computed tomography. *Pediatrics* 2006 Aug;118(2):626-33.
- 200a. Vezina G. Assessment of the nature and age of subdural collections in nonaccidental head injury with CT and MRI. *Pediatr Radiol* 2009;39:586-590.
201. Slovis TL, Smith W, Kushner DC, et al. Imaging the child with suspected physical abuse. American College of Radiology. ACR Appropriateness Criteria. *Radiology* 2000; 215 (Suppl):805-809.
202. Slovis TL, Smith WL, Strain JD, et al. Expert Panel on Pediatric Imaging. Suspected physical abuse--child. [online publication]. Reston (VA): American College of Radiology (ACR); 2005. 5 p. [33 references].
203. Alexander RC, Schor DP, Smith WL Jr. Magnetic resonance of intracranial injuries from child abuse. *J Pediatr* 1986; 109: 975-979.
204. Sato Y, Yuh WT, Smith WL, et al. Head injury in child abuse: evaluation with MRI. *Radiology* 1989; 173: 653-657.
205. Ball WS Jr. Nonaccidental craniocerebral trauma (Child Abuse): MR imaging. *Radiology* 1989; 173:609-610.
206. Hart BL, Dudley MH, Zumwalt RE. Postmortem cranial MRI and autopsy correlation in suspected child abuse. *Am J Forensic Med Pathol* 1996; 17: 217-224.
207. Haseler LJ, Arcnue E, Danielsen ER, et al. Evidence from proton MR spectroscopy for a metabolic cascade of neuronal damage in shaken baby syndrome. *Pediatrics* 1997; 99: 4-14.
208. Feldman KW, Weinberger E, Milstein JM, Fligner CL. Cervical spine MRI in abused infants. *Child Abuse Negl* 1997; 21: 199-205.
209. Ewing-Cobbs L, Kramer L, Prasad M, et al. Neuroimaging, physical, and developmental findings after inflicted and noninflicted traumatic brain injury in young

children. *Pediatrics* 1998; 102: 300-307.

210. Rooks VJ, Sisler C, Burton B. Cervical spine injury in child abuse: report of two cases. *Pediatr Radiol* 1998; 28: 193-195.

211. Chabrol B, Decarie JC, Fortin G. The role of cranial MRI in identifying patients suffering from child abuse and presenting with unexplained neurological findings. *Child abuse Negl* 1999; 23: 217-228.

212. Barlow KM, Gibson RJ, PcPhillips M, Minns RA. Magnetic resonance imaging in acute nonaccidental head injury. *Acta Pediatr* 1999; 88: 734-740.

213. Bruce D. Imaging after head trauma: why, when and which. *Child's Nerv Syst* 2000;16:755-799.

214. Suh, D, Davis P, Hopkins K, et al. Nonaccidental pediatric head injury: diffusion-weighted imaging findings. *Neurosurgery* 2001;49:309-320.

215. Ichord R, Naim M, PollackA, et al. Hypoxic-ischemic injury complicates inflicted and accidental traumatic brain injury in young children: the role of diffusion-weighted imaging. *J Neurotrauma* 2007;24:106-118.

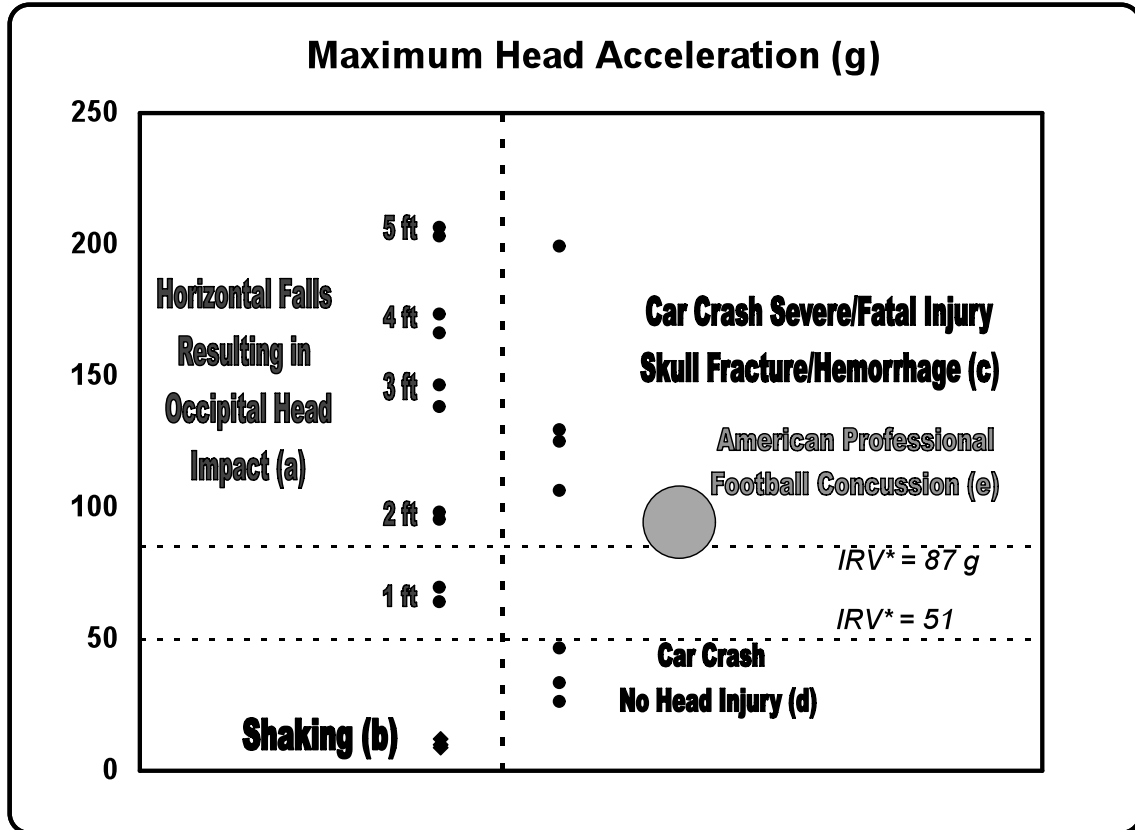
216. Zuerrer M, Martin E, Boltshauser E. MRI of intracranial hemorrhage in neonates and infants at 2.35 Tesla. *Neuroradiology* 1991;33:223-229.

217. Barkovich A. *Pediatric Neuroimaging*, Philadelphia, Lippincott-Raven, 2005, 190-290.

218. Fullerton HJ, Johnston SC, Smith WS. Arterial dissection and stroke in children. *Neurology*. 2001;57:1155-60.

219. Zouros A, Bhargava R, Hoskinson M, et al. Further characterization of traumatic collections of infancy. *J Neurosurg (Pediatrics)* 2004;100;512-518.

Table 1 - Maximum Head Accelerations vs. Trauma Mechanisms as Correlated with Injury Thresholds



•Chris Van Ee Ph.D. Design Research Engineering (www.dreng.com); Leestma J. Forensic Neuropathology, 2nd Ed, CRC Press, Boca Raton FL, 2009.

•Mertz H, Anthropomorphic Test Devices, Chapter 4, pg 84, Accidental Injury: Biomechanics and Prevention, 2nd Edition, Editors: Melvin J, Nahum A, Springer, 2002. Child Restraint Air Bag Interaction (CRABI).

•Klinich JD, Hulbert G, Schneider LW, Estimating Infant Head Injury Criteria and Impact Response Using Crash Reconstruction and Finite Element Modeling, Society of Automotive Engineers Paper # 2002-22-0009, 2002. CRABI 12 (a,b); CRABI 6 (c,d); Injury Reference Values (IRV).

•Pellman EJ, Viano DC, Tucker AM, Casson IR, Waeckerle JF. Concussion in professional football: reconstruction of game impacts and injuries (e). Neurosurgery. 2003 Oct;53(4):799-812

Table 2 - MRI of Intracranial Hemorrhage & Thrombosis*

STAGE	BIOCHEMICAL FORM	SITE	T1-MRI	T2-MRI
Hyperacute (+edema)	Fe II oxyHb	Intact RBCs	Iso-Low I	High I

[<12 hours]

Acute (+edema) [1-3 days]	Fe II deoxy Hb	Intact RBCs	Iso-Low I	Low I
Early Subacute (+edema) [3-7 days]	Fe III metHb	Intact RBCs	High I	Low I
Late Subacute (-edema) [1-2 weeks]	Fe III metHb	Lysed RBCs (extracellular)	High I	High I
Early Chronic (-edema) [>2 weeks]	Fe III transferrin	Extracellular	High I	High I
Chronic (cavity)	Fe III ferritin & hemosiderin	Phagocytosis	Iso-Low I	Low I

*RBCs - red blood cells, I - signal intensity, + present, - absent, Hb - hemoglobin, Fe II - ferrous, Fe III - Ferric, Iso - isointense.

Barkovich A. Pediatric Neuroimaging, 4th edition, Philadelphia, Lippincott-Raven, 2005, 190-290.

Zuerrer M, Martin E, Boltshauser E. MRI of intracranial hemorrhage in neonates and infants at 2.35 Tesla. *Neuroradiology* 1991;33:223-229

Barnes P, Krasnokutsky M. Imaging of the CNS in suspected or alleged nonaccidental injury, including the mimics. *Top Magn Reson Imaging* 2007;18 (1): 53-74.