

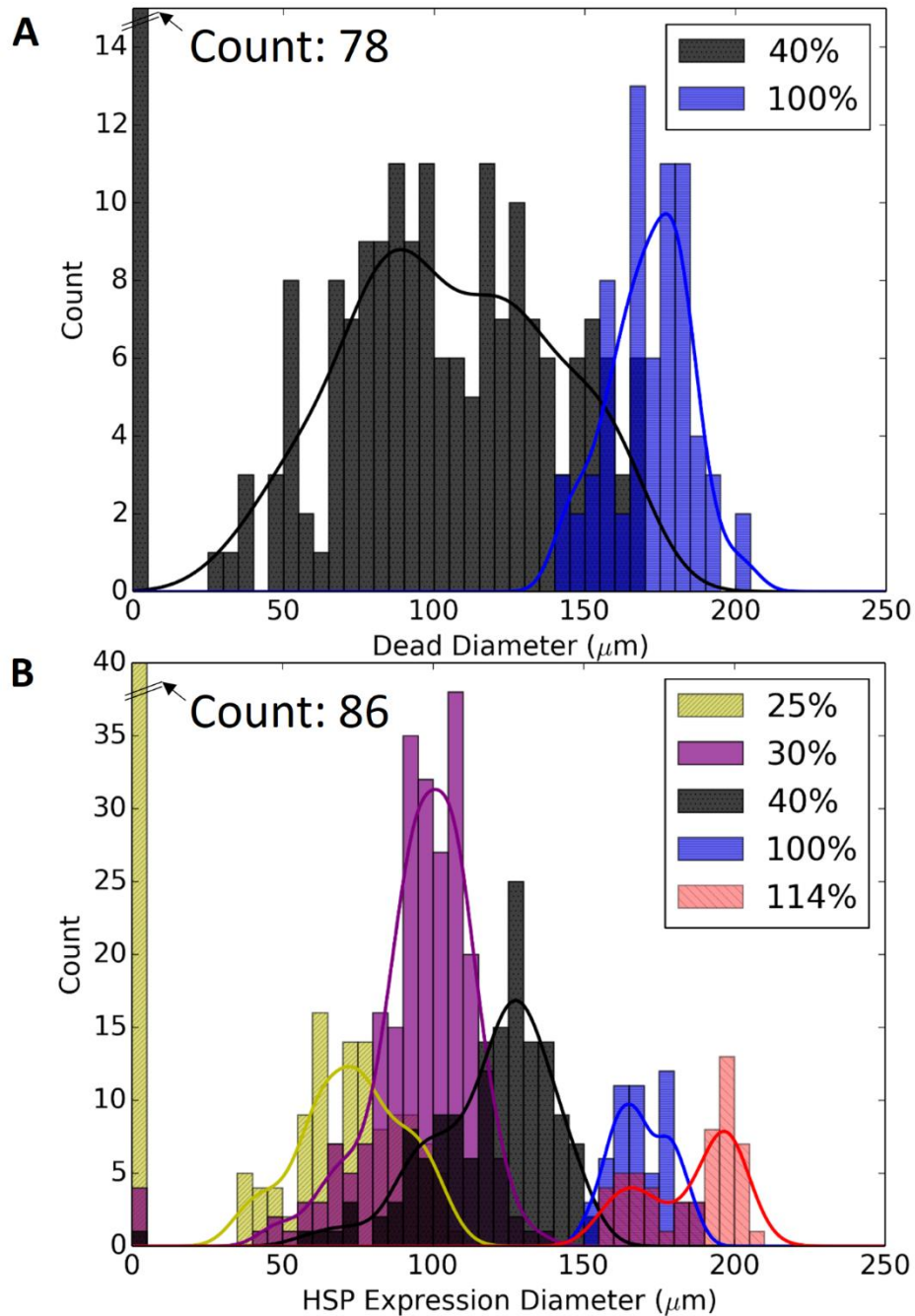Fig. S1. Distribution of tissue response to laser treatment. **(A)** Histogram of the diameters of the damage on the RPE after 40% (black) and 100% (blue) laser treatment. Kernel density estimation is done by fitting the non-zero values. **(B)** Distribution of the outer diameter of HSP expression zone on RPE at various laser settings.

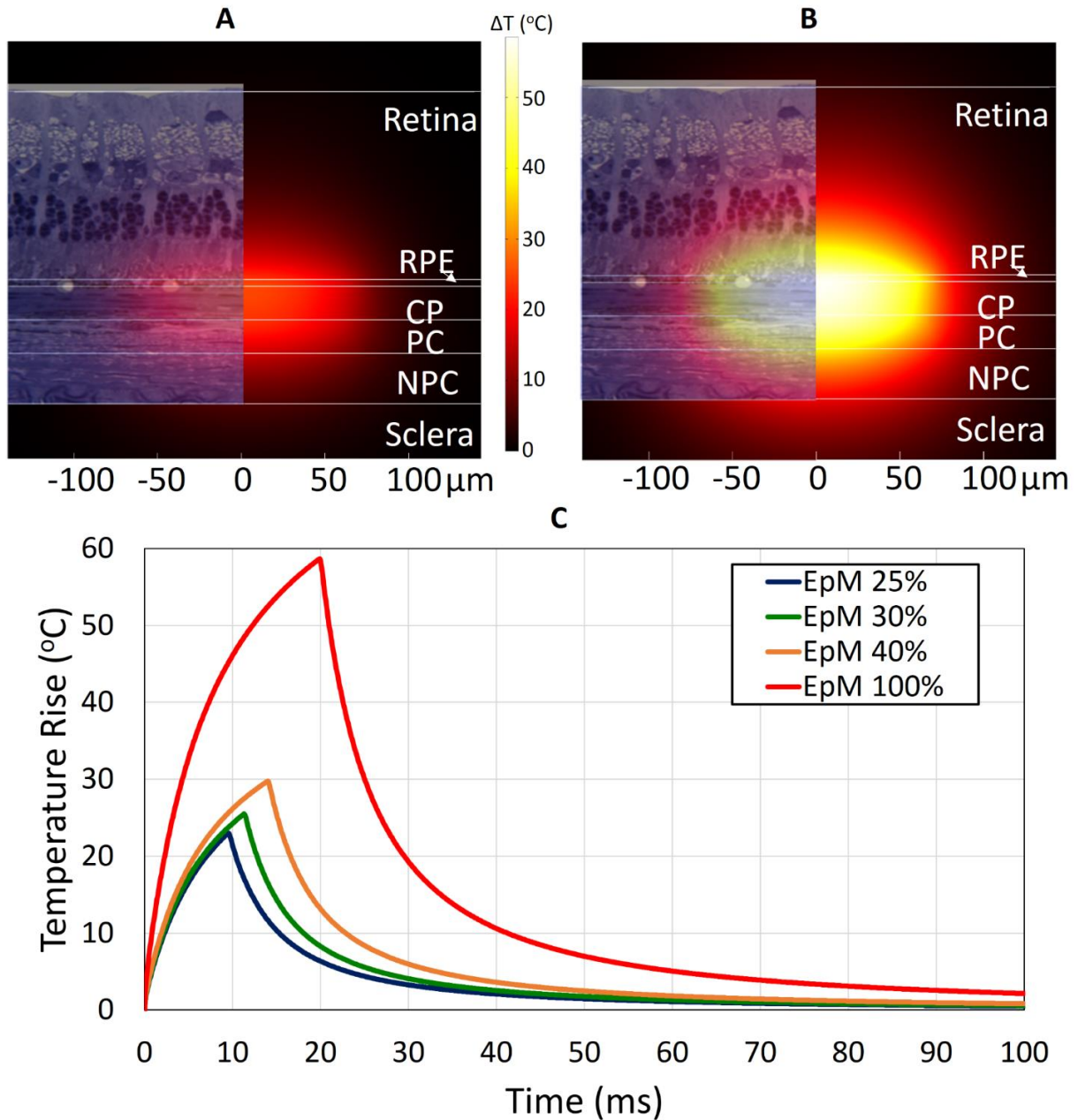


Fig. S2. Computational model of laser heating. Cross section map of maximum temperature rise after (A) 30% laser exposure and (B) 100% laser exposure. (C) Time course of the temperature rise on RPE at middle of laser spot for various laser settings.

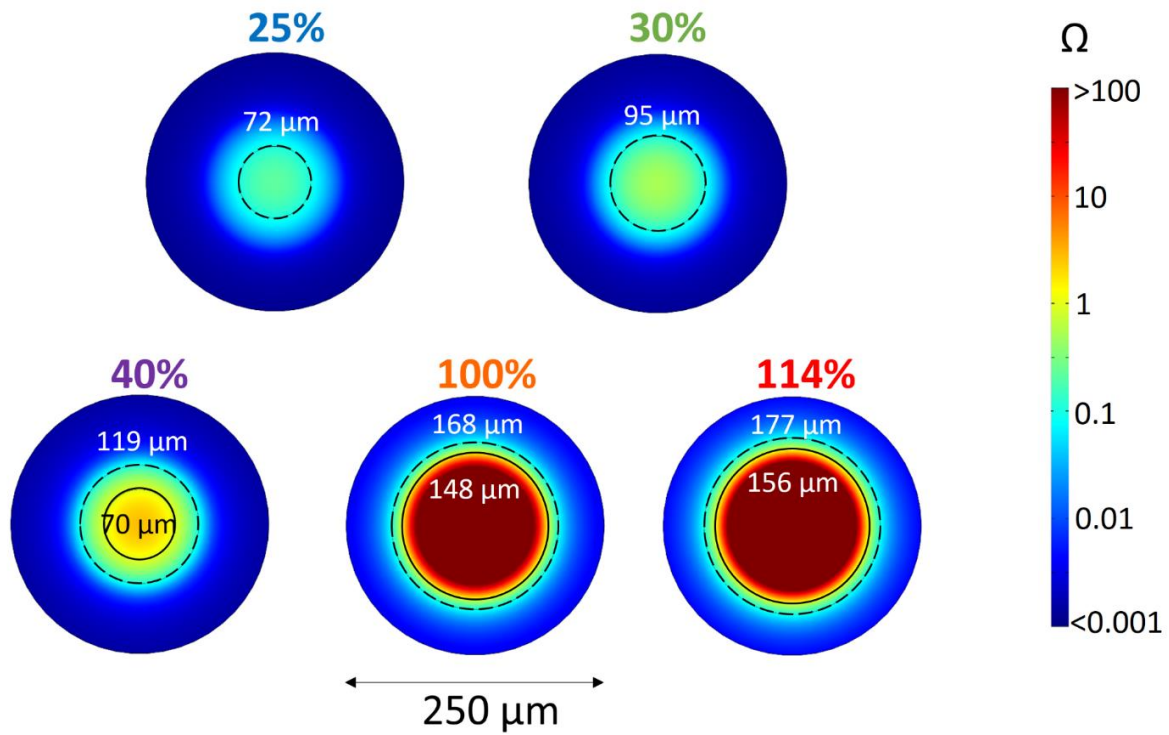


Fig. S3. Surface plots of Arrhenius integral after laser exposure. Dotted lines indicate $\Omega = 0.1$ contour and solid lines indicate $\Omega = 1$. These are the predicted bounds of HSP expression.

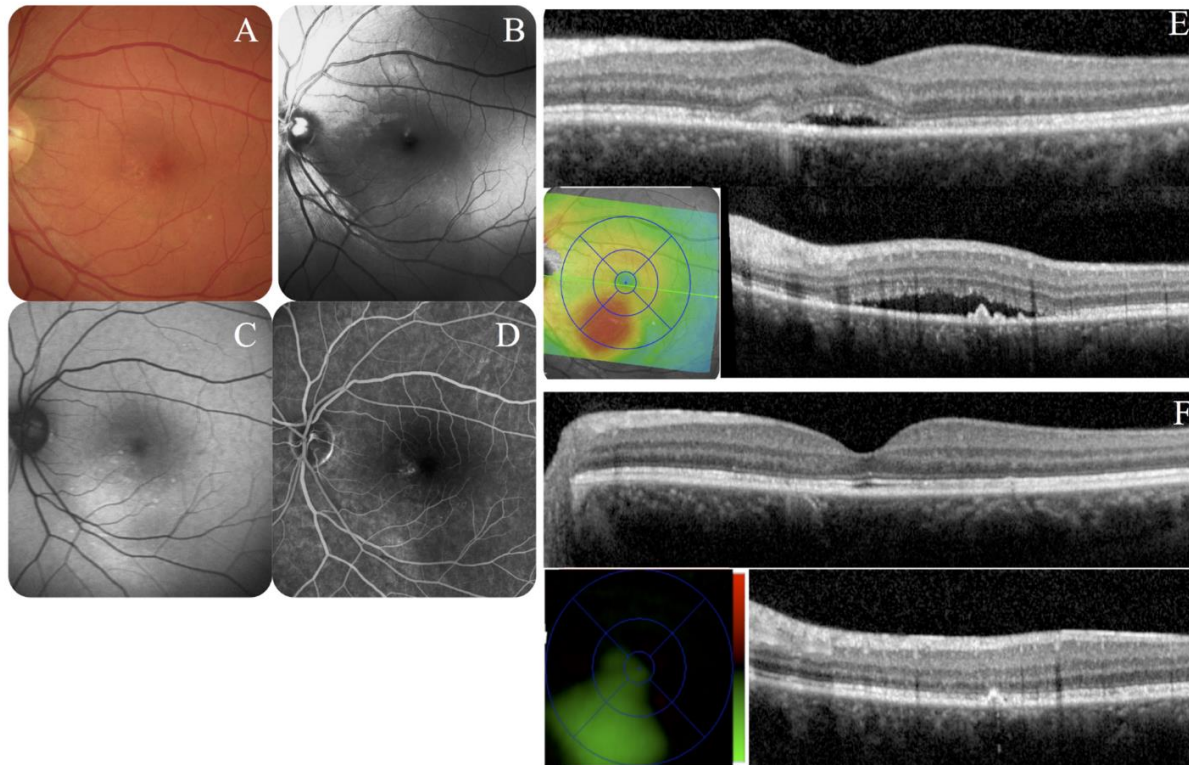


Fig. S4. Example #2 of CSCR patient. Baseline (A) color fundus, (B) blue reflectance, (C) autofluorescence, (D) fluorescein angiography and (E) OCT with subfoveal (top) and inferior subretinal (bottom) fluid visible on color map. The color scale ranges from -400 to 400 μm . One month after treatment, the subretinal fluid was resolved and visual acuity increased from 20/40 to 20/15. (F). One year after a single treatment, subretinal fluid is still absent, with significantly reduced retinal thickness shown on color map, and visual acuity remaining at 20/15.

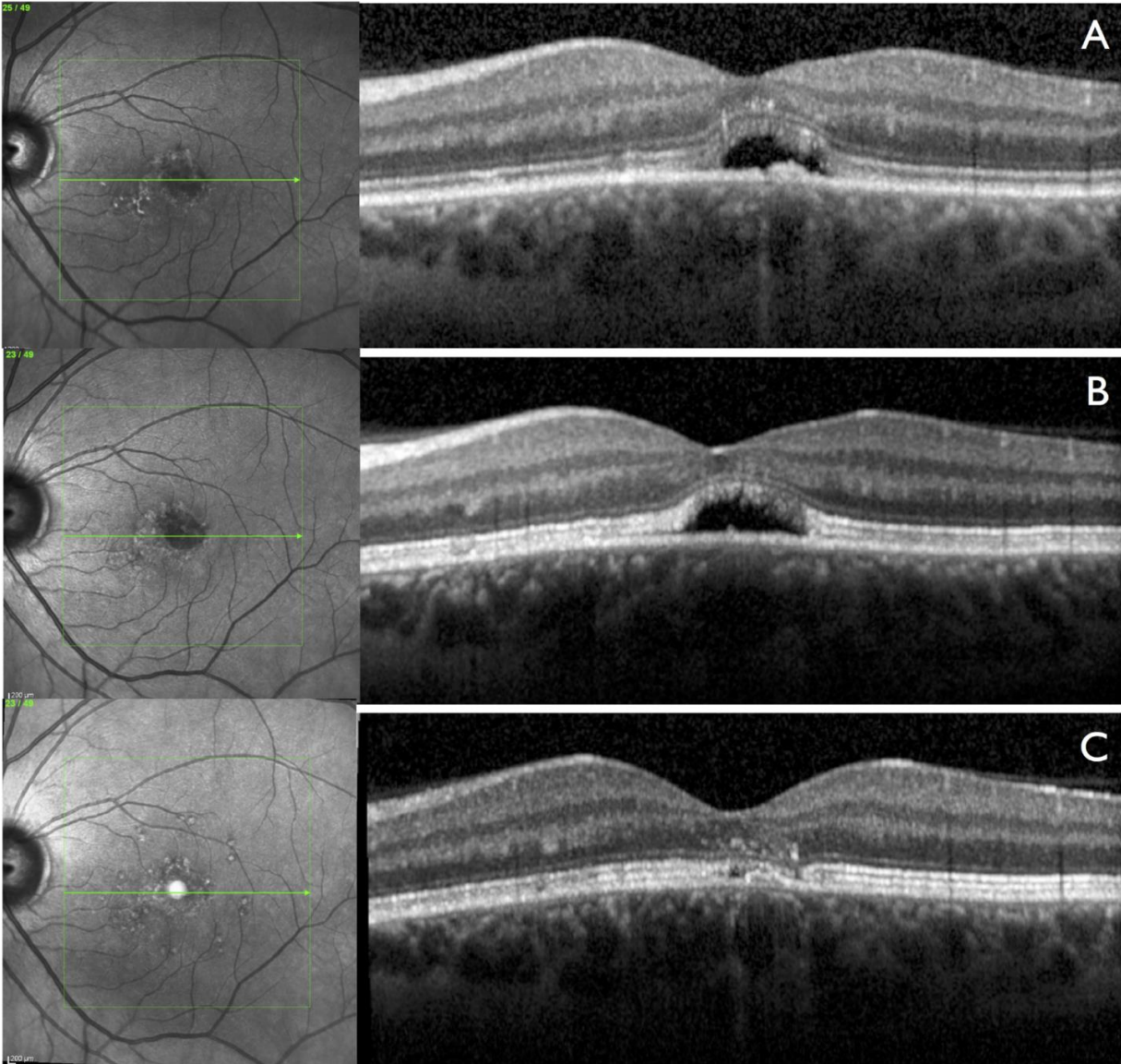


Fig. S5. Example #3 of CSCR patient. **(A)** First OCT on onset of symptoms in 2012. **(B)** Baseline OCT with no spontaneous resolution of subretinal fluid after one year. **(C)** Complete resolution of subretinal fluid three months after the laser treatment, which remained stable for one year.

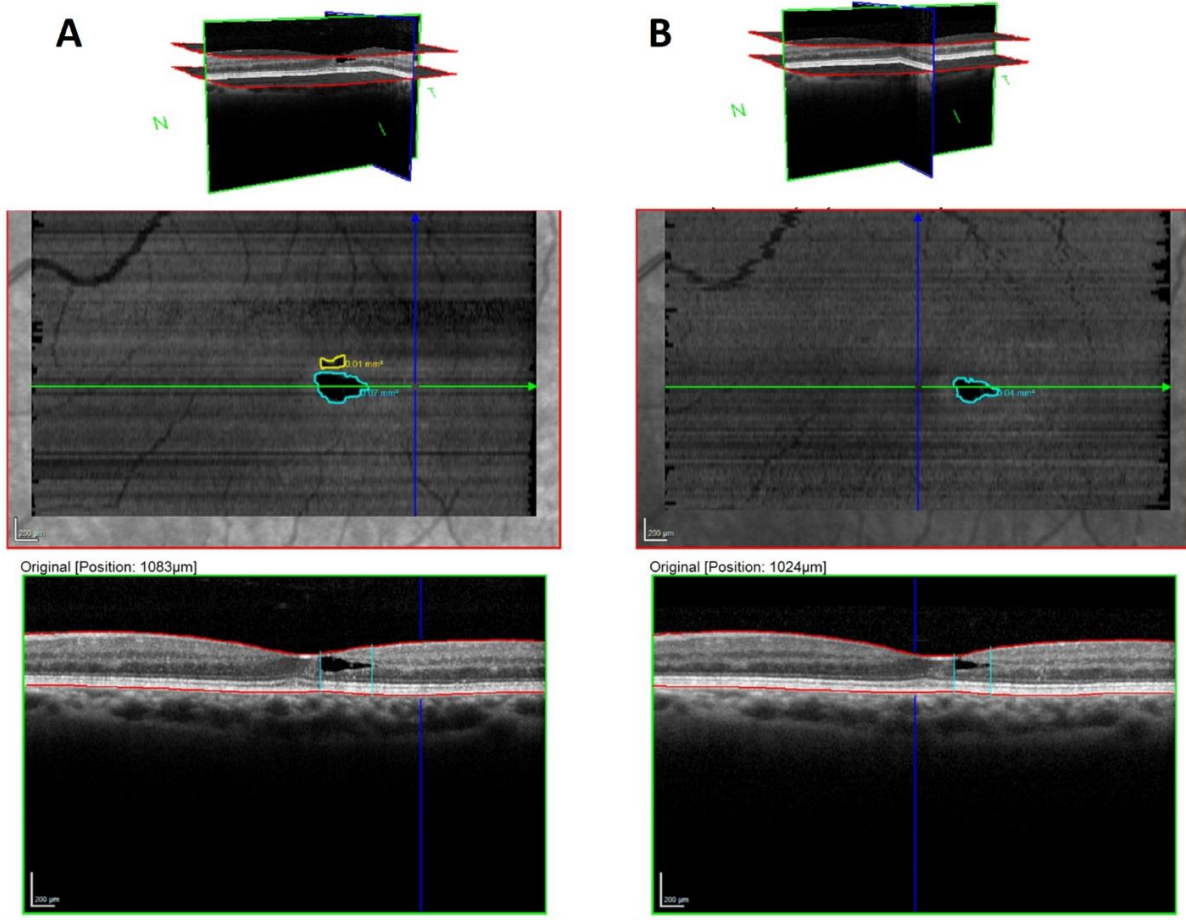


Fig. S6. Example of MacTel patient. **(A)** Baseline OCT with volume rendering (top), en face view (middle), single image scan (bottom). Two lacunae are visible with areas of 0.07 and 0.01 mm². **(B)** OCT 12 months after laser treatment showing 50% reduction in lacunae area.

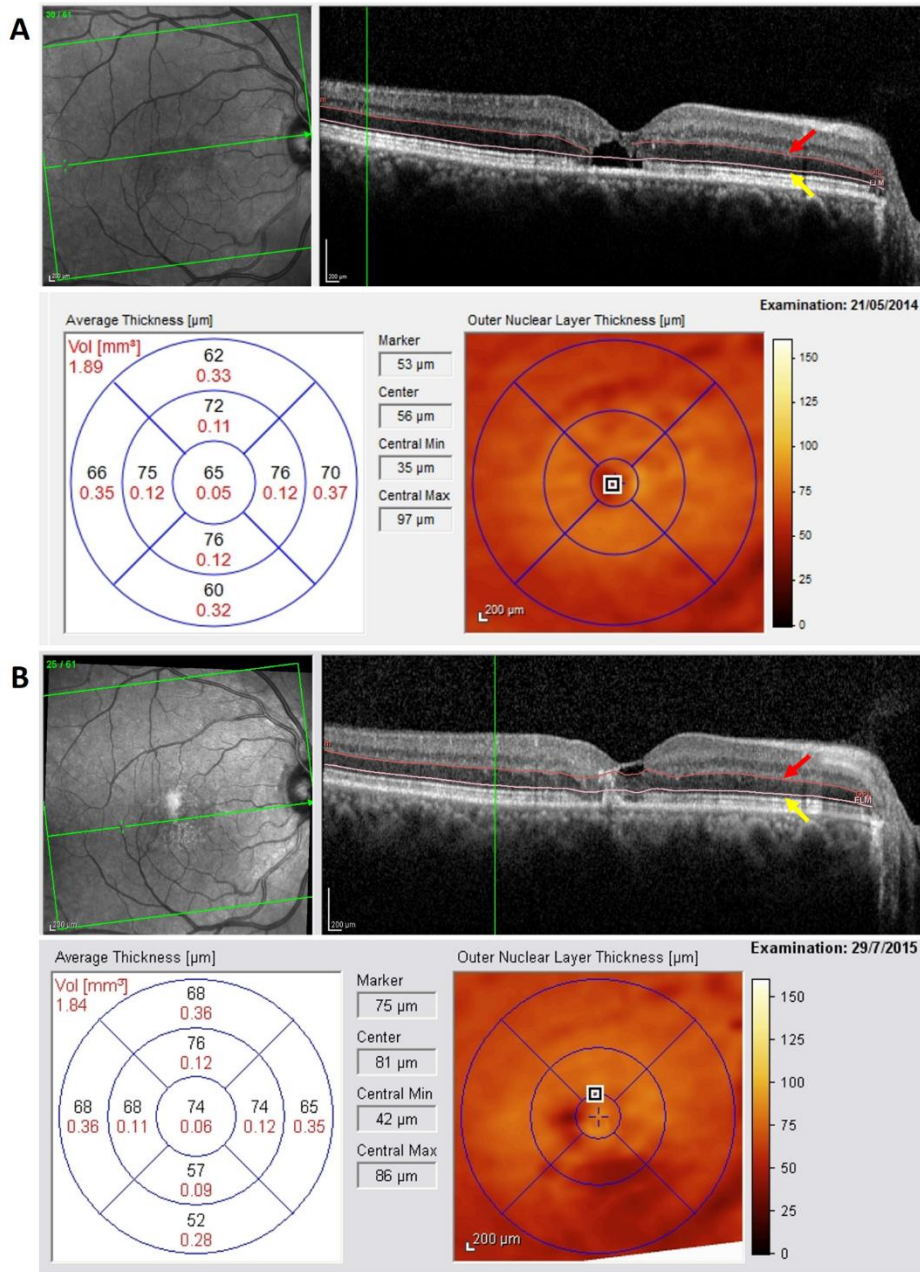


Fig. S7. Detailed retinal thickness map from MacTel case **(A)** Baseline central outer nuclear layer with decreased thickness due to foveal cavitation. Red arrow indicates line showing outer plexiform layer (OPL) segmentation while yellow arrow indicates line showing external limiting membrane (ELM) segmentation. The outer nuclear layer thickness is calculated as the distance between these layers. **(B)** After 12 months, there was an increase of 12μm on central outer nuclear thickness.